



IPF



















CASEBOOK

特發性肺纖維化
案例集

VOL.1

IPF CASEBOOK

Table of Content

Prologue.....	02	
I. Diagnosis of IPF.....	05	
• Typical case (UIP)	07	
• Atypical case (possible UIP, without honeycombing)	15	
• IPF with emphysema	21	
• Asymmetric IPF	31	
• IPF with lung cancer	37	
II. Differential Diagnosis of IPF.....	44	
• End-stage CHP	46	
• Drug induced	54	
• NSIP (Sjögren's syndrome)	60	
III. Treatment of IPF.....	66	
• IPF treated with nintedanib	68	
• Nintedanib treatment for IPF: management of side effects	75	
• Lung transplantation for IPF	81	
IV. IPF Clinical Course.....	89	
• IPF with AE	91	
• End-stage IPF	99	

The term "idiopathic pulmonary fibrosis" (IPF) first appeared in the medical literature in the mid-1900s, and it was initially used by pulmonologists and radiologists to refer to fibrosing pneumonitis with an unknown cause. The diagnostic complex is now termed idiopathic interstitial pneumonias (IIPs,) includes several disease entities in addition to IPF, such as interstitial lung disease (ILD) associated with connective tissue disorders (CTD) and fibrotic hypersensitivity pneumonitis (HP). These disease entities are often wrongly identified as IPF by clinicians because of the similar clinical presentations and radiographic appearance. Over the past several decades, progress in histopathology has paved the way for the current clinicopathological classification of IIPs. It has become clear that the term IPF should be exclusively applied to patients with idiopathic usual interstitial pneumonia (UIP). An IIPs taskforce was formed by the Taiwan Society of Pulmonary and Critical Care Medicine (TSPCCM). This taskforce has endeavored to generate educational programs and materials for all medical disciplines, not merely pulmonologists, involved in the diagnosis and management of IIPs. The IPF casebook is the first of a series of publications produced by TSPCCM. It includes 13 IPF cases with detailed clinical, laboratory, imaging, and pathological data, and we believe that readers will find this casebook practical and useful.



Chong-Jen Yu 余忠仁

Chong-Jen Yu , M.D., Ph.D.

President, Taiwan Society of Pulmonary and Critical Care Medicine, Taiwan
Professor, College of Medicine, National Taiwan University
Vice Superintendent, National Taiwan University Hospital

The IPF CASEBOOK is a learning module that delivers a concise review of our current understanding the disease through interpretations of high-resolution computed tomography images and provides useful data regarding the diagnosis and management of this disease, which will aid in clinical practice and make a valuable contribution to the medical literature. Each chapter includes key points and a summary to update clinicians about various issues concerning the diagnosis and management of IPF. In addition to outlining the current state of knowledge, each chapter also provides a summary of the clinical experience in Taiwan and identifies the need for future research in the field. The IPF CASEBOOK is an important new text that provides its readers with a better understanding of the radiological features and natural course of IPF as it continues to evolve.



Yeun-Chung Chang 張允中

Yeun-Chung Chang, M.D., Ph.D.

President, The Radiological Society of the Republic of China (RSROC), Taiwan
Professor and Director, Department of Radiology, National Taiwan University College of
Medicine
Chairman, Department of Medical Imaging, National Taiwan University Hospital

Idiopathic pulmonary fibrosis (IPF) is a disease that affects the alveoli and leads to serious lung damage; the idiopathic nature indicates that the origin or cause is unknown. Physicians should be aware of the early stages and symptoms of this disease in order to implement management strategies in a timely fashion and deliver best treatment.

The IPF CASEBOOK is easily accessible and is an excellent quick reference tool for pulmonologists and other health care professionals. The full color images and figures enhance and summarize the key aspects of IPF.

Each chapter includes key points and a summary to update clinicians about various issues concerning the diagnosis and management of IPF. In addition to outlining the current state of knowledge, each chapter also identifies the unmet requirement for future research in the field.

The described cases highlight the heterogeneity in the presentation, history, and clinical course of IPF, together with expert insight regarding the diagnosis and management of this disease in a real-life setting.

I hope that this book and the many outstanding, informative chapters penned by experts in the field will serve as a platform and spur even more interest in this enigmatic disease.



Hao-Chien Wang 王鶴健

Hao-Chien Wang, M.D., Ph.D.

Professor of Internal medicine, College of Medicine, National Taiwan University
Chief of Medical Intensive Care Unit, National Taiwan University Hospital, Taiwan

I. Diagnosis of IPF



Diagnosis of IPF

IPF is defined as a chronic, progressive, fibrosing interstitial pneumonia of unknown cause, occurring primarily in older adults, and limited to the lungs. The 2011 ATS, ERS, JRS, and ALAT statements represent significant advances in the diagnosis of IPF: specifically, CT findings alone can be used to diagnose UIP without the need for tissue confirmation. Importantly, CT findings also offer additional information to further categorize IPF patients into sub-groups and different clinical phenotypes. In this chapter, cases of UIP, possible UIP, UIP combined with emphysema, and the asymmetric distribution of the UIP pattern are presented, and valuable comments are highlighted for each case.



Typical case (UIP)

A Case of Idiopathic Pulmonary Fibrosis

Dr. Tang-Hsiu Huang

Division of Chest Medicine,
Department of Internal Medicine,
National Cheng Kung University, College of Medicine and
Hospital,
Tainan, Taiwan

Clinical pearls

- IPF is typically a disease seen in older patients (mostly >50 years of age), and appears to affect more men than women.
- When evaluating patients suspected to have IPF, a comprehensive assessment of the patient history and thorough physical examination are crucial to identify risk factors and typical symptoms and signs, and to exclude other possible etiologies for lung disease. Pulmonary function tests and HRCT are the two most important diagnostic tests for IPF.
- According to the current guidelines, the diagnosis of IPF, in addition to compatible clinical presentation and typical findings from pulmonary function testing, requires the following:
 - The exclusion of other possible etiologies for UIP / ILD;
 - HRCT findings showing UIP patterns in patients for whom surgical lung biopsy is not possible;
 - Both HRCT and pathologic examination findings showing UIP patterns in patients undergoing surgical lung biopsy.
- Multi-disciplinary evaluations involving specialists in the relevant fields would be helpful in establishing the diagnosis and are therapeutic strategies, and is strongly recommended according to current guidelines.

Patient profile

Case presentation

The patient was a 71-year-old male retired high-school teacher living in southern Taiwan. He was referred to our Chest Medicine Clinic for the first time in December 2014. He presented with exertion-induced dyspnea (corresponding to mMRC scale 1) and an intermittent dry cough. The symptoms were slowly progressive, and were unrelated to postural or seasonal changes. He had no fevers and no symptoms involving the skin or joints, nor did he complain about discoloration of his finger tips upon exposure to cold or dryness in his eyes and mouth.

Medical history

- Positive history of GERD (diagnosed in 2015, and subsequently treated with a PPI and H2-blocker), critical aortic stenosis (status post mechanical valvular replacement in 2004), hypertension, dyslipidemia, type II diabetes mellitus, and stage 3 chronic kidney disease
- Positive history of cigarette smoking (0.5 PPD for > 20 years; quit in 2015), but negative for other substance abuse
- Unremarkable family history

Physical examination findings

- SpO₂: 95% while at rest on ambient air
- Regular heart beat at 85 bpm
- Bibasilar inspiratory "velcro crackles" without wheezes or rhonchi
- No weakness or edema of the extremities
- No deformity or clubbing of the fingers
- No rashes, cracking, or sclerodactyly of the skin

Laboratory panels (data nearest in time to the date of diagnosing IPF are listed)

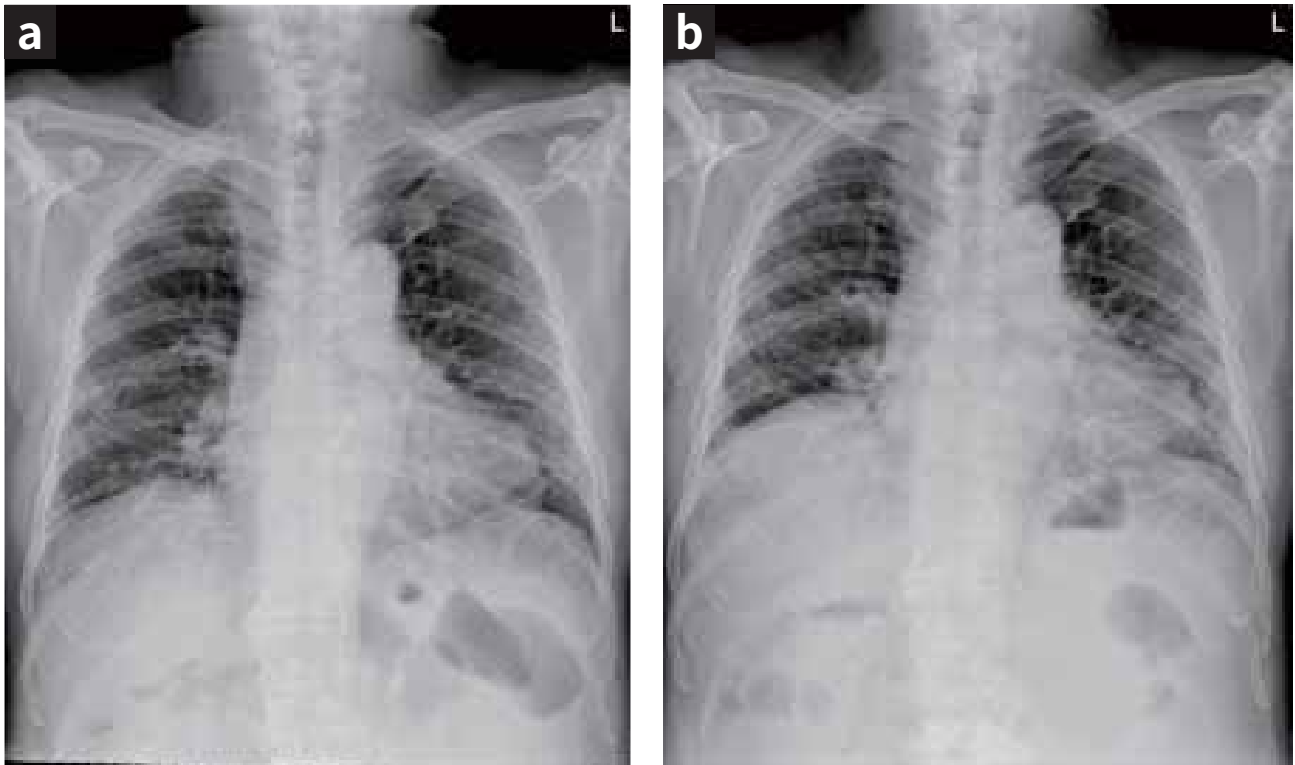
Date	Blood test (unit)	Result	Reference
2014/02	WBC (10 ³ /uL)	9.8	3.4-9.1
	Neutrophils(%)	73.6	43.0-64.0
	Eosinophils (%)	1.3	0.0-6.0
	Basophils (%)	0.6	0.0-1.0
	Monocytes (%)	8.8	3.0-9.0
	Lymphocytes (%)	15.7	27.0-47.0
	Hemoglobin (g/dL)	13.9	13.5-17.0
	Platelets (10 ³ /uL)	220	138-353
	Creatinine (mg/dL)	2.27	0.70-1.20
2015/06	Creatinine (mg/dL)	2.27	0.70-1.20
	Alanine aminotransferase, [ALT] (U/L)	21	10-50
	Albumin / Total protein (g/dL)	4.4 / 8.1	3.50-5.50 / 6.4-8.3
	Creatinine kinase, [CK] (U/L)	140	39-308
2014/11	Glycated hemoglobin, [HbA1c] (%)	6.0	4.0-6.0
2014/12	Anti-nuclear antibodies, [ANA]	1:40 speckled	< 1:40
	Rheumatoid factor, [RF] (IU/mL)	< 20	< 20
	Complement 3, [C3] (mg/dL)	101.0	58.0-147.0
	Complement 4, [C4] (mg/dL)	26.3	11.0-35.0
2015/12	Anti-SSA/Ro antibodies (U/mL)	150 [#]	< 10
	Anti-SSB/La antibodies (U/mL)	1.0	< 7
	Anti-Scl-70 antibodies (U/mL)	0.4	< 7
	Anti-Jo-1 antibodies (U/mL)	0.3	< 7
2014/01	Hepatitis C antibody	negative	negative
2014/01	Hepatitis B surface antigen	negative	negative

[#]: The results of salivary scintigraphy and Schirmer's test in 2016 were reported as normal.

Radiological imaging studies

- Serial chest postero-anterior (PA) radiographs show cardiomegaly and sternal wiring due to valvular replacement, with a reticular infiltrate that was predominantly noted in the lower and peripheral lung fields and progressively increased from 2014/12 (Figure 1a) to 2017/2 (Figure 1b).

Figure 1a-1b



- Serial chest CT studies show progressively increasing UIP reticulation, honeycombing, and traction bronchiectasis, predominantly in the subpleural and basal zones (Figures 2a – 2i and 3a – 3c).
- The CT findings are consistent with those of usual interstitial pneumonia (UIP). 5-mm non contrast chest CT image at the upper (Figure 2a, 2d), mid (Figure 2b, 2e) and basal (Figure 2c, 2f) lung zones. HRCT with 1 mm thickness at the upper (Figure 2g), mid (Figure 2h) and basal (Figure 2i) lung zones.

Figure 2a - 2i

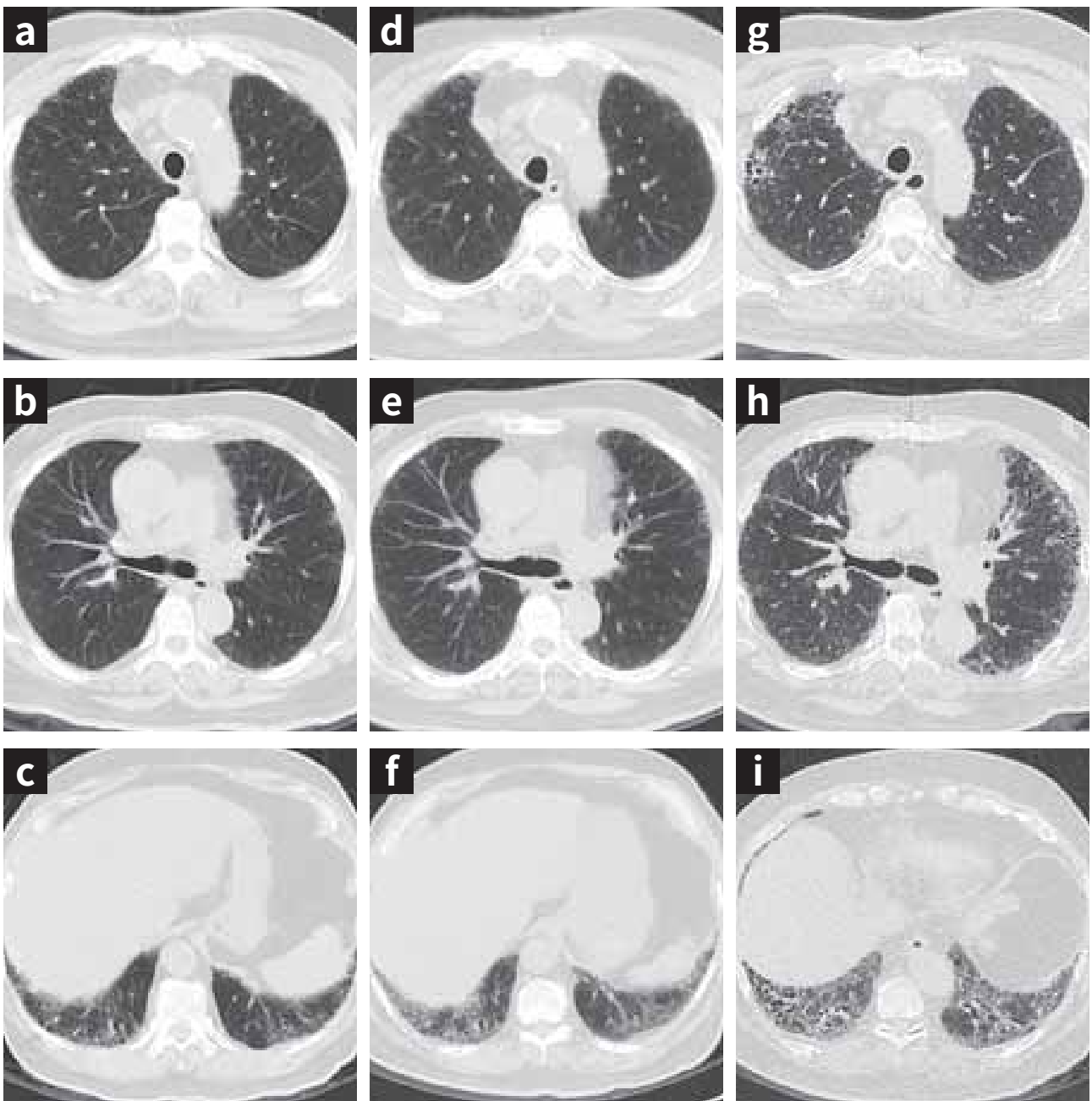


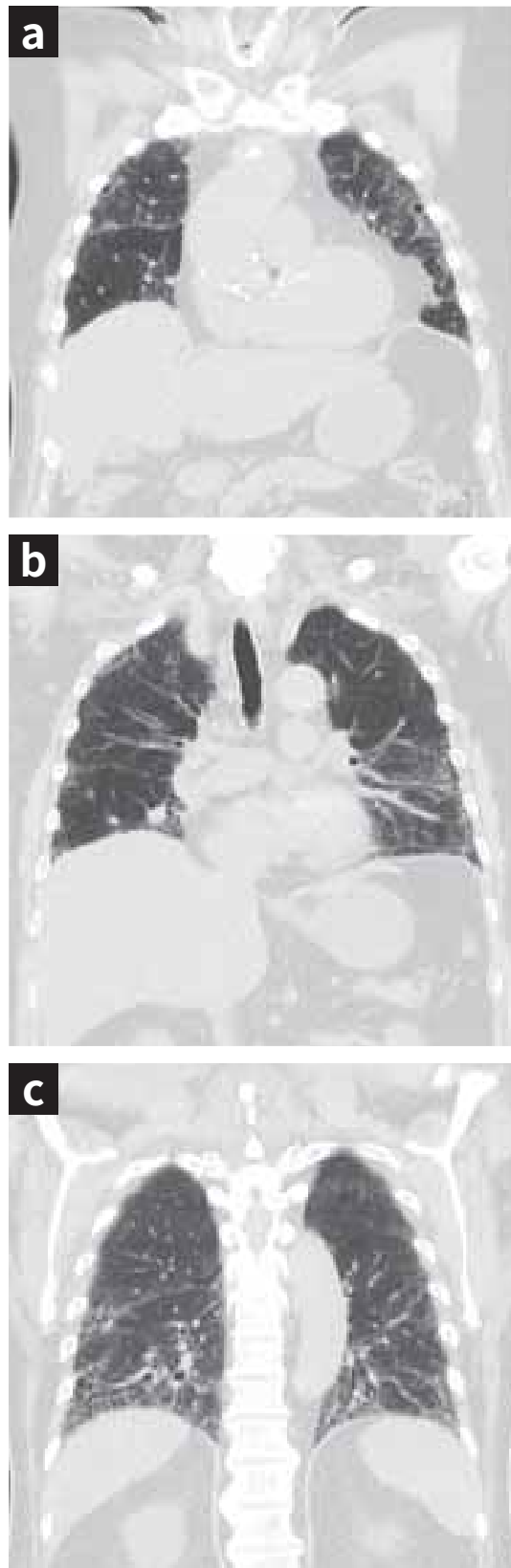
Figure 2a - 2c(2012/09)

Figure 2d - 2f(2014/12)

Figure 2g - 2i(2017/04)

Typical CT finding for the UIP pattern, showing an increased extent of reticulation, honeycombing and traction bronchiectasis (Figure 2a-2i).

Figure 3a – 3c



Coronal CT images obtained in 2017/04 show the subpleural and basal distribution of reticulation and honeycombing traction bronchiectasis (consistent with typical UIP pattern).

Cytologic and pathologic studies

- Bronchoscopic lavage and surgical lung biopsy were not performed due to the patient's refusal and also because of concerns over his poor pulmonary function.

Serial pulmonary function tests

Date	FVC (L)	FVC (% predicted)	FEV ₁ (L)	FEV ₁ (% predicted)	TLC (L)	TLC (% predicted)	D _{LCO} (% predicted)
2014/01	2.55	78	2.19	91			
2014/12	2.77	85	2.35	99	3.67	70	
2015/10	2.23	69	1.97	86	3.54	68	60
2016/08	2.24	70	1.90	84			54
2017/04	1.81	56	1.61	71			60
2017/10 [#]	1.82	57	1.50	68	2.91	56	43

Final diagnosis

Idiopathic pulmonary fibrosis (GAP index 5 points and stage 3 in 2017/10)

Abbreviations

BPM, beats per minute; CTD, connective tissue disease; D_{LCO}, diffusion capacity of the lung for carbon monoxide; FEV₁, forced expiratory volume in one second; FVC, forced vital capacity; GERD, gastro-esophageal reflux disease; HRCT, high-resolution computed tomography; ILD, interstitial lung disease; IPF, idiopathic pulmonary fibrosis; PPI, proton pump inhibitor; TLC, total lung capacity; UIP, usual interstitial pneumonia

References

1. Raghu G, Collard HR, Egan JJ, Martinez FJ, Behr J, Brown KK, et al. An official ATS/ERS/JRS/ALAT statement: idiopathic pulmonary fibrosis: evidence-based guidelines for diagnosis and management. *Am J Respir Crit Care Med* 2011;183 (6):788-824.
2. Raghu G, Rochwerg B, Zhang Y, Garcia CA, Azuma A, Behr J, et al. An Official ATS/ERS/JRS/ALAT Clinical Practice Guideline: treatment of idiopathic pulmonary fibrosis. An update of the 2011 Clinical Practice Guideline. *Am J Respir Crit Care Med* 2015; 192 (2): e3-e19.
3. An Official American Thoracic Society/European Respiratory Society statement: update of the international multidisciplinary classification of the idiopathic interstitial pneumonias. *Am J Respir Crit Care Med* 2013; 188 (6): 733-748.
4. Sgalla G, Biffi A, Richeldi L. Idiopathic pulmonary fibrosis: diagnosis, epidemiology and natural history. *Respirology* 2016; 21: 427-437.



Atypical case (possible UIP, without honeycombing)

Atypical case (possible UIP,
without honeycombing)

Dr. Pin-Kuei Fu

Department of Critical Care Medicine,
Taichung Veterans General Hospital,
Taichung, Taiwan

Clinical pearls

- The typical HRCT findings of IPF include bibasilar, peripheral, and reticular opacities associated with architectural distortion, including honeycombing and traction bronchiectasis.
- Honeycombing is defined as clusters of cystic airspaces, approximately 3–10 mm in diameter, and are usually located in the subpleural regions.
- While honeycombing is essential for the definitive diagnosis of UIP, honeycombing may be absent in some cases.
- Approximately half of the cases with biopsy-proven UIP do not show a clear HRCT pattern owing to the absence of typical findings (such as honeycombing). Such atypical HRCT patterns observed in UIP are very similar or identical to those of NSIP.
- Therefore, the latest ATS/ERS/JRS/ALAT guidelines outlined the HRCT features that meet the criteria for "definite UIP," "possible UIP," and "inconsistent with UIP."
- For uncertain diagnoses, surgical lung biopsy should be used, along with the histologic data, to diagnose IPF.
- Follow-up HRCT might be required for patients presenting with an unexpected clinical-functional decline, or in cases of non-definite UIP pattern on HRCT that cannot be characterized by lung biopsy.

Patient profile

Case presentation

- 77-year-old woman
- A housewife residing in central Taiwan
- Intermittent dry cough and progressive dyspnea on exertion, over the last 3 years
- Concomitant weight loss of 5 kg

Medical history

- No history of peptic ulcer disease
- Non-smoker; no alcohol consumption or drug usage
- No pets
- Unremarkable family medical history

Physical examination

- Heart rate: 96 bpm
- SpO₂: 93% in ambient air
- Bibasilar crackles on auscultation
- Nail clubbing
- No lower extremity edema
- No arthralgia
- No skin rashes

Laboratory findings

- Normal CBC and biochemistry results
- RF-, ANA-, anti-ENA-, and anti-CENP-negative; normal C3 and C4 levels
- Negative bacterial, mycobacterial, and fungal cultures

Pulmonary function test findings

Parameter	Value
FVC	70% predicted
FEV ₁	73% predicted
FEV ₁ /FVC	82%
FEV _{25-75%}	75% predicted
TLC	76% predicted
D _{LCO}	77% predicted

Conclusion

Mild decrease in TLC and D_{LCO}.

Radiological imaging studies

Figure 1: Chest radiography findings

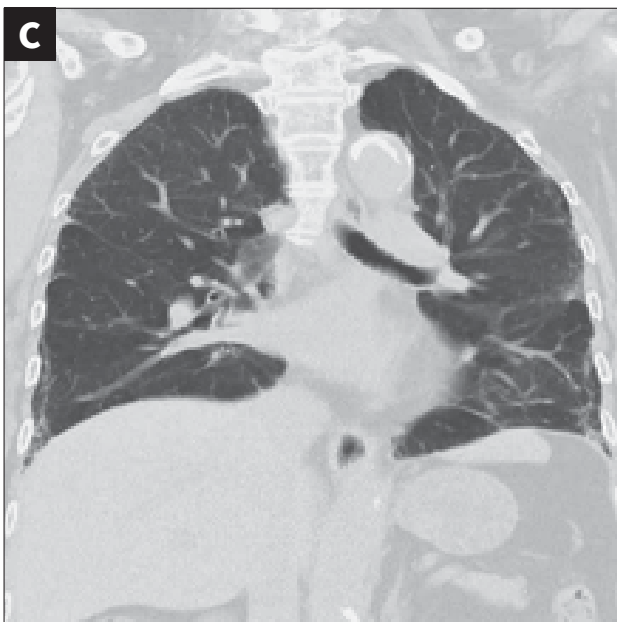
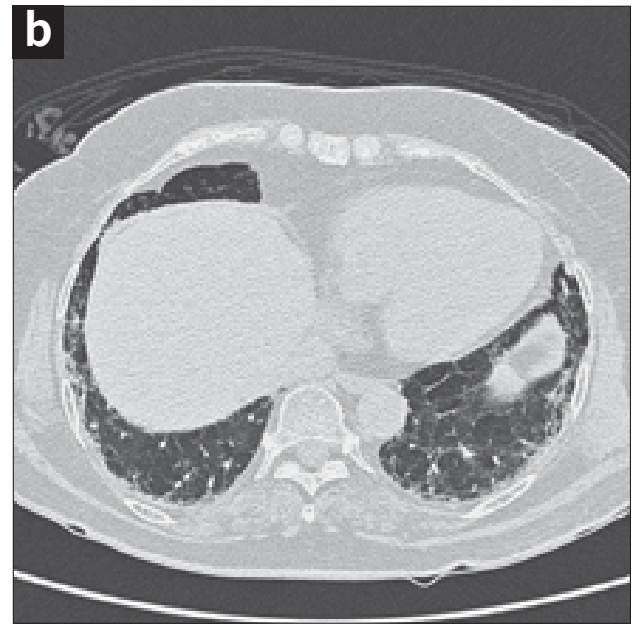
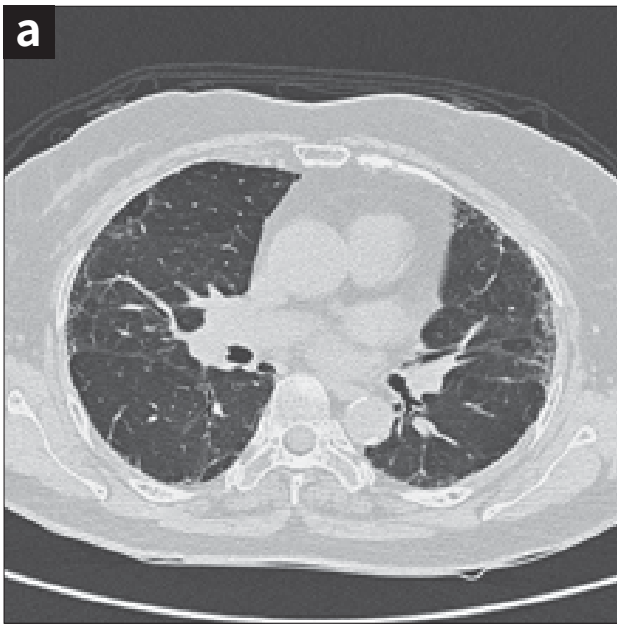
Chest radiograph findings: reticular infiltrates, distributed equally in both lungs. They are more in number at the lung periphery, without obvious difference between the upper and lower regions.

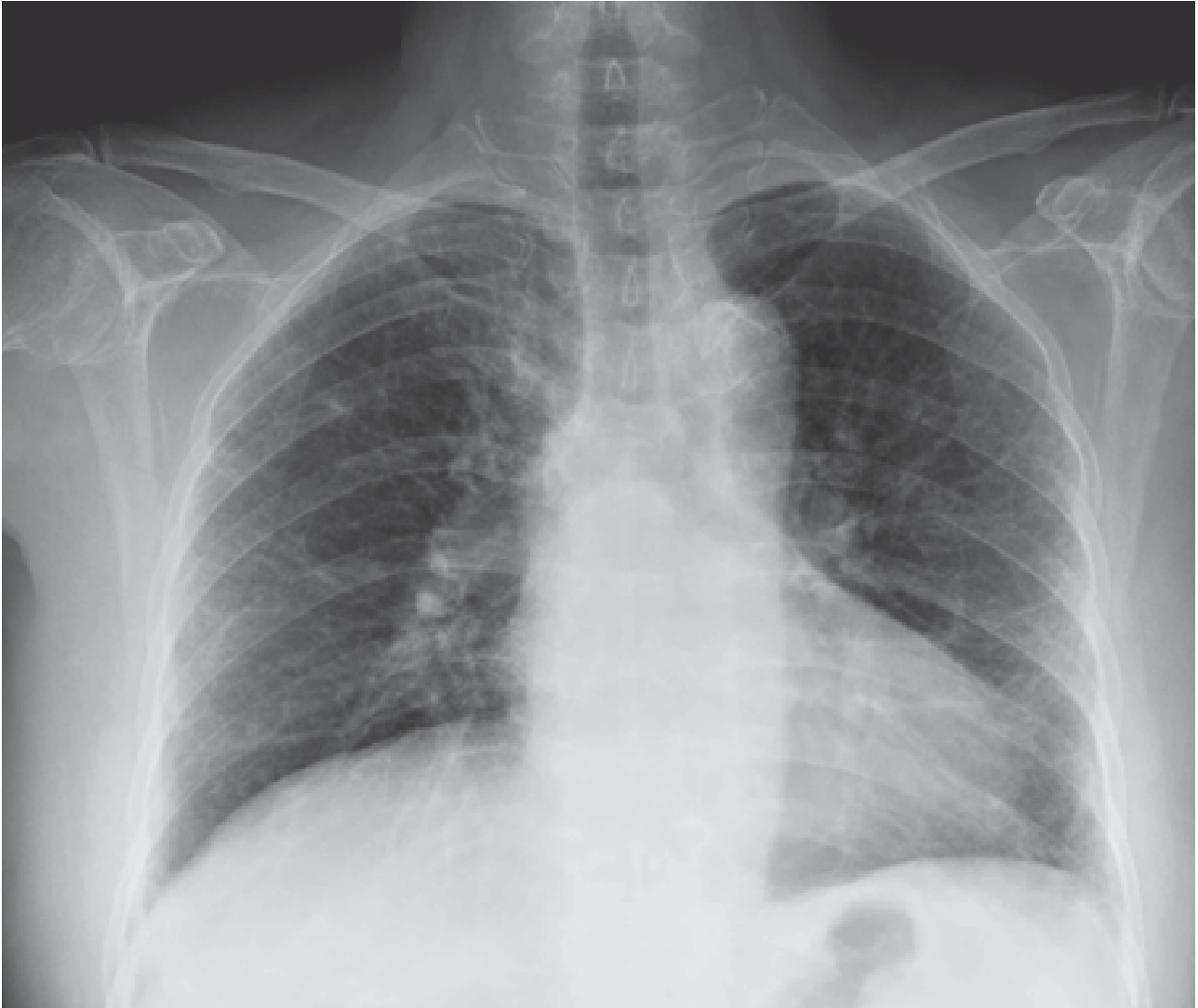
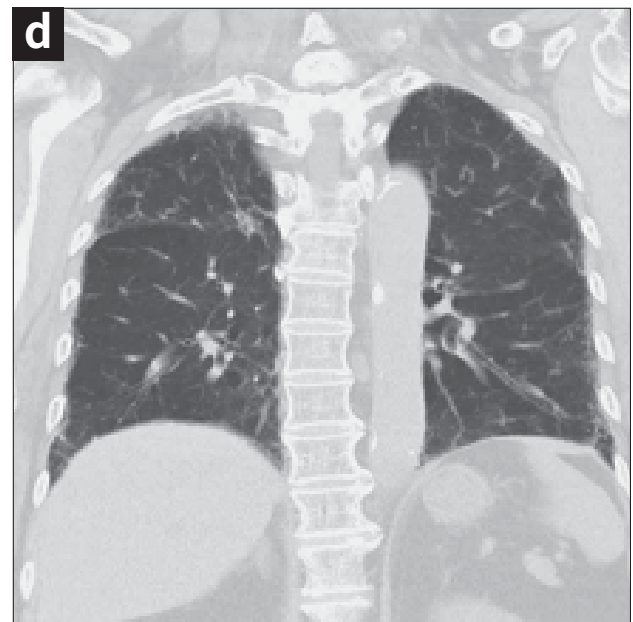
Figure 2a-2b: HRCT findings

Patterns typical of usual interstitial pneumonia (UIP) can be observed:

- Traction bronchiectasis, with irregular reticulation in the subpleural region of both lungs
- Absence of honeycombing pattern with the typical apico-postero-basal gradient.



Pulmonary function test (follow-up)

Date	FVC (L)	FVC (% predicted)	FEV ₁ (L)	FEV ₁ (% predicted)	D _{LCO} (% predicted)
2016.12.09	1.70	70	1.39	73	77
<ul style="list-style-type: none">• Initiation of pulmonary rehabilitation• Initiation of influenza vaccination					
2017.03.31	1.60	66	1.33	71	69
<ul style="list-style-type: none">• Initiation of pneumococcus vaccination• Initiation of nintedanib (150 mg) administration, twice a day (in May 2017)					
2017.07.31	1.64	68	1.23	65	55
2017.10.20	1.66	72	1.32	72	64

Abbreviations

ALAT, Latin American Thoracic Association; ATS, American Thoracic Society; ERS, European Respiratory Society; HCRT, high-resolution computed tomography; IPF, idiopathic pulmonary fibrosis; JRS, Japanese Respiratory Society; NSIP, non-specific interstitial pneumonia; UIP, usual interstitial pneumonia

References

1. Raghu G, Rochwerg B, Zhang Y, Garcia CA, Azuma A, Behr J, et al. An official ATS/ERS/JRS/ALAT clinical practice guideline: Treatment of idiopathic pulmonary fibrosis. An update of the 2011 clinical practice guideline. *Am J Respir Crit Care Med* 2015; 192:e3–19.
2. Hodnett PA, Naidich DP. Fibrosing interstitial lung disease. A practical high-resolution computed tomography-based approach to diagnosis and management and a review of the literature. *Am J Respir Crit Care Med* 2013; 188:141–9.
3. Gruden JF, Panse PM, Gotway MB, Jensen EA, Wellnitz CV, Wesselius L. Diagnosis of usual interstitial pneumonitis in the absence of honeycombing: Evaluation of specific CT criteria with clinical follow-up in 38 patients. *AJR Am J Roentgenol* 2016; 206:472–80.
4. Sverzellati N. Highlights of HRCT imaging in IPF. *Respir Res* 2013; 14(Suppl 1):S3.
5. Kuschner JE, Martin MD, Kanne JP. Imaging of idiopathic pulmonary fibrosis. *Radiol Clin North Am* 2016; 54:997–1014



IPF with Emphysema

**Idiopathic pulmonary fibrosis
with emphysema:
A different phenotype and a
case of combined pulmonary
fibrosis and emphysema
syndrome**

Dr. Yi-Hung Pan, Dr. Chi-Cheng Lin

Division of Chest Department,
Antai Medical Care Cooperation Antai Tian-Sheng
Memorial Hospital,
Pingtung, Taiwan

Clinical pearls

- Combined pulmonary fibrosis and emphysema (CPFE) is characterized by upper lung zones emphysema co-existing with lower lobe fibrosis.
- Patients with CPFE have a preserved FVC and FEV₁ with severe symptoms of dyspnea and exercise hypoxemia, and decreased in the D_{LCO}.
- CPFE most often occurs in elderly male smokers.
- Pulmonary hypertension is highly prevalent and a leading cause of death in these patients.

Patient profile

Case presentation

- 73-year-old man
- Ex-fisherman
- Progressive dyspnea on exertion since 1 year

Medical history

- Coronary artery disease treated with aspirin and bisoprolol for 10 years
- Hypertension treated with a combination of olmesartan, amlodipine and hydrochlorothiazide for 10 years
- History of tobacco use (one pack per day for 40 years);
- Abstinence smoking for >10 years
- No alcohol or drug use
- No pets
- Unremarkable family history

Physical examination

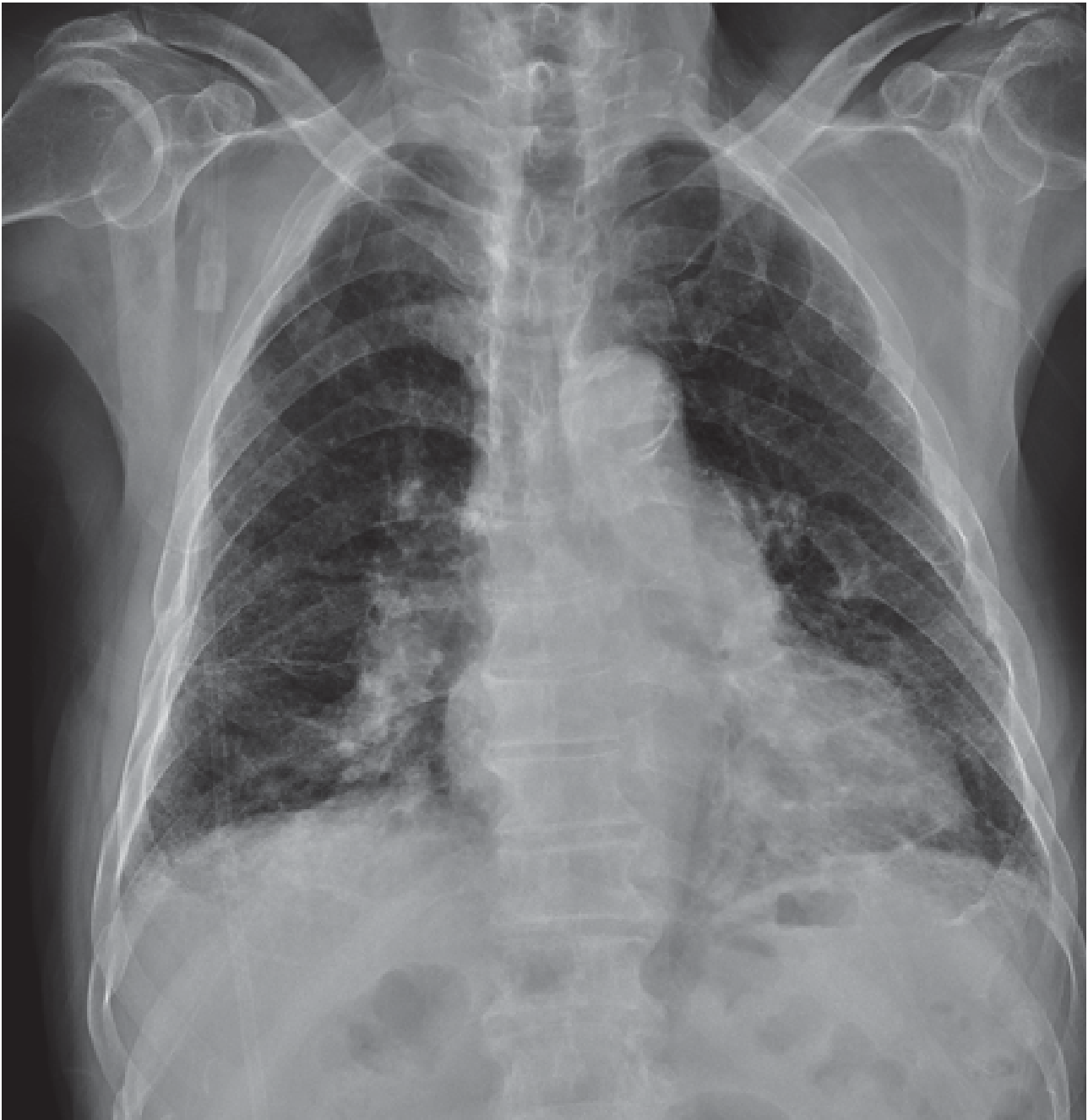
- Heart rate: 85 bpm
- SpO₂: 81% on ambient air after walking , 92% when resting for 1 h
- Bibasilar crackles on auscultation
- Nail clubbing (+)
- No leg edema
- No arthralgias

Laboratory findings

- Normal CBC and biochemistry results
- RF, ANA, anti-ENA and anti-CENP negativity; normal C3 and C4 levels
- Negative bacterial, mycobacterial, and fungal cultures

Figure 1: Chest radiography findings

Reticular infiltrates can be observed in the lung and subpleural regions. The lung density is decreased in the upper fields, mainly on the left side. This is consistent with pulmonary emphysema. Cardiomegaly, mainly right heart enlargement and an engorged pulmonary trunk can be seen.



Pulmonary function test findings

Parameter	Value
FVC	56.3% predicted
FEV ₁	63.3% predicted
FEV ₁ / FVC	81.5%
FEF _{25%-75%}	53.9% predicted
TLC	n/a
D _{LCO}	n/a

Conclusion: Moderately decreased of FVC, FEV₁, and FEF_{25%-75%}

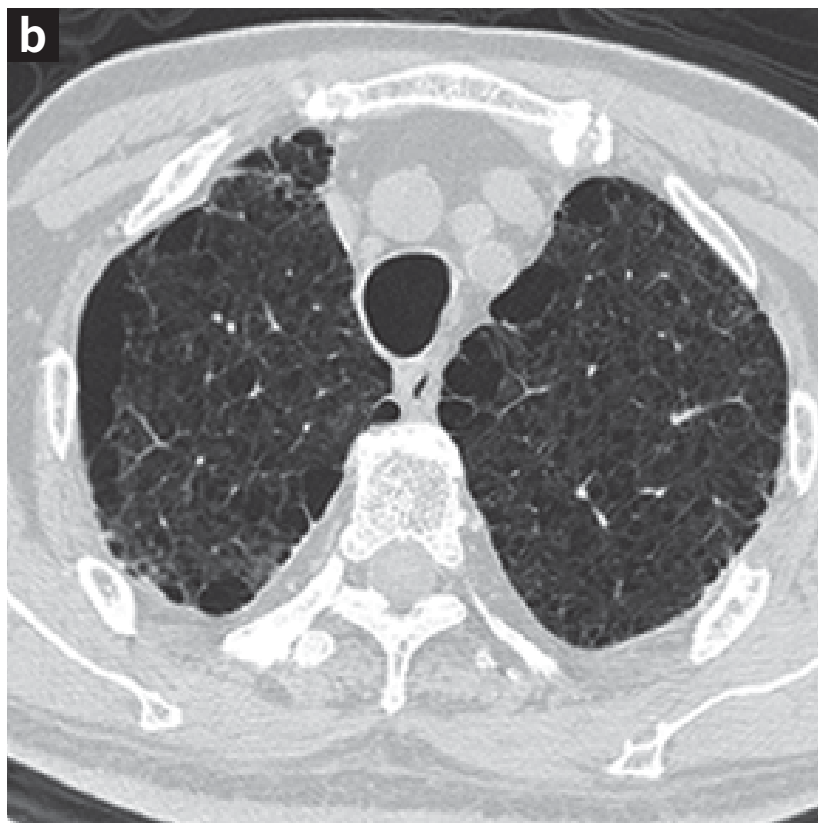
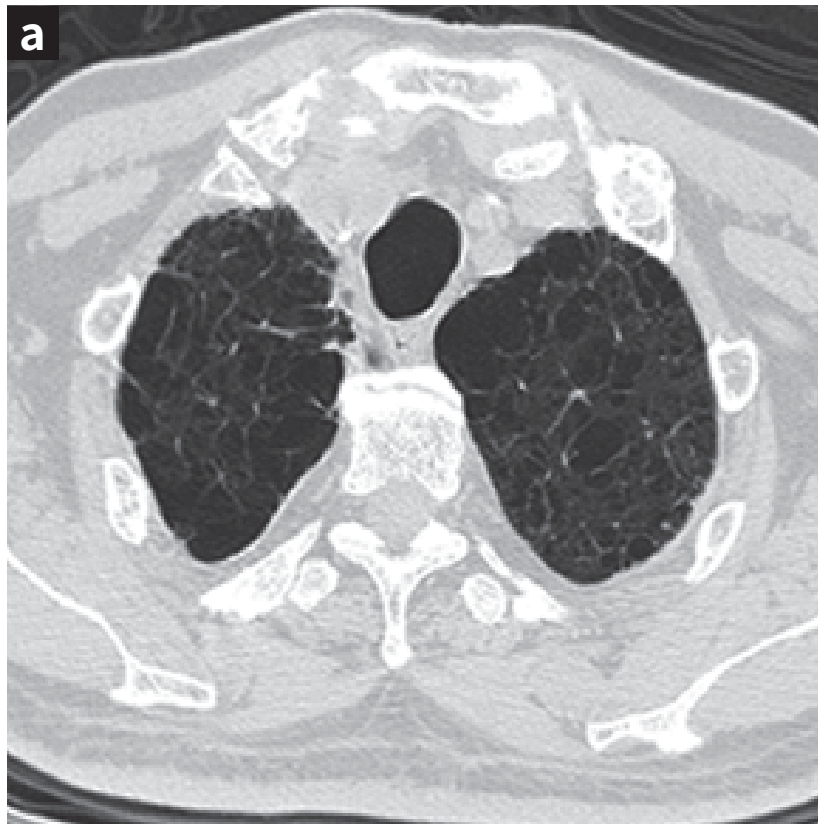
Cardiac evaluation

- TRPG = 45 mmHg

Figure 2a-2d: HRCT findings

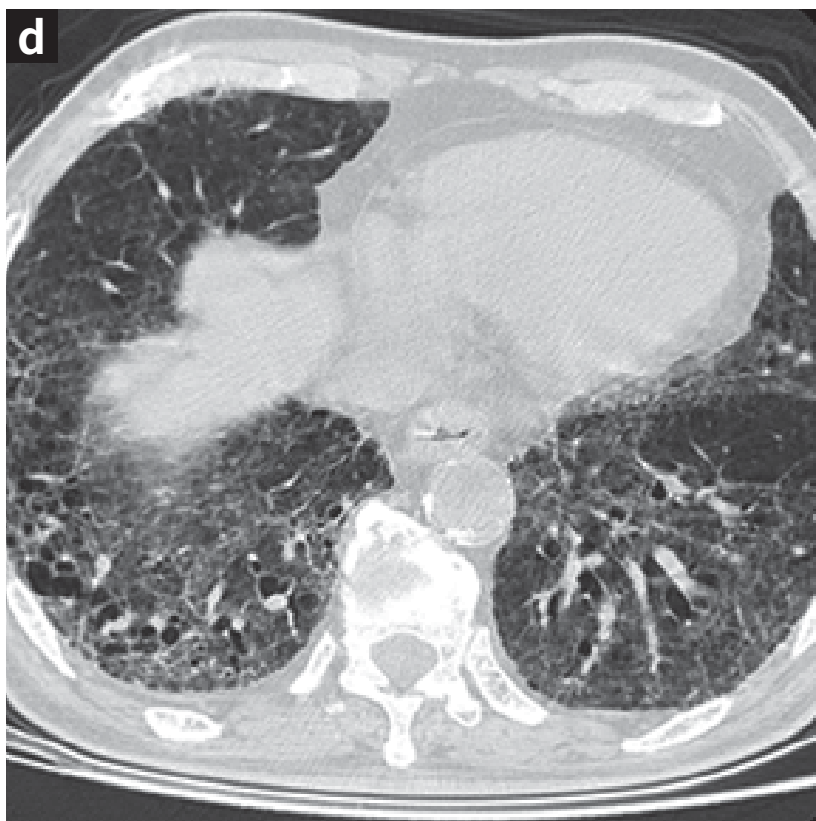
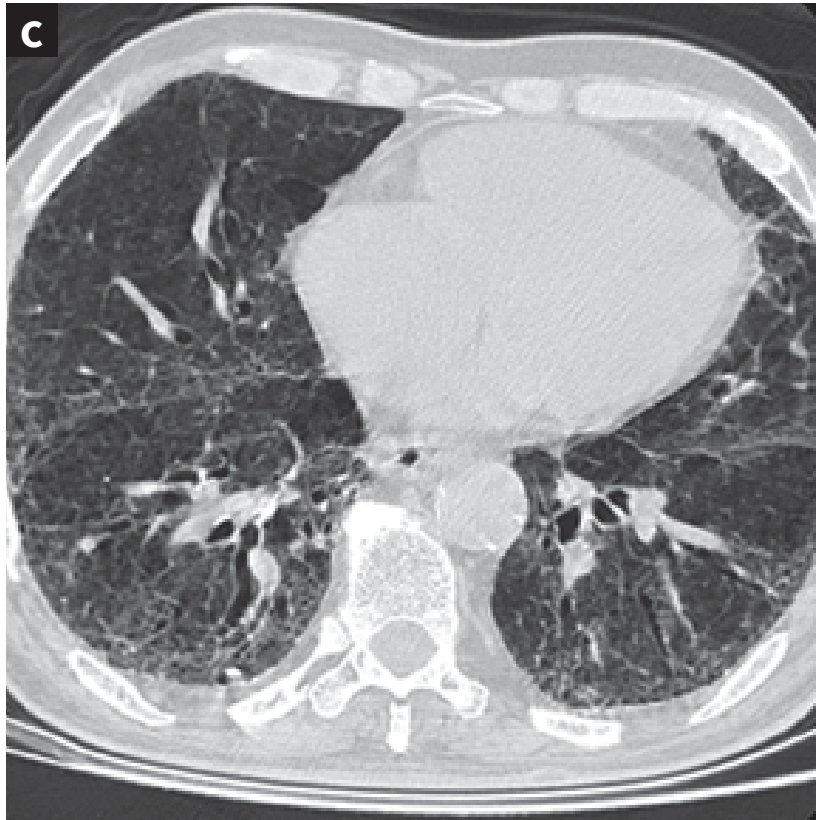
Emphysema

- Bilateral centrilobular (upper lobe) and subpleural emphysema can be seen.



UIP pattern

- Bilateral traction bronchiectasis can be observed in the posterobasal region of the lower lung lobe, along with subpleural honeycombing and bilateral honeycombing pattern in the basal region of the lower lobe.



Clinical course

- Unlike IPF without emphysema, CPFE shows severe exercise hypoxemia with reserved FVC and FEV₁. CPFE cannot be evaluated by FVC because of the rate of clinical decline. In this case, he presented with moderately decreased FVC (56.3% of predicted), even 3 months before death.

Date	FVC (L)	FVC (% predicted)	FEV ₁ (L)	FEV ₁ (% predicted)	FEV ₁ / FVC (%)
2016/.02	2.05	70.0	1.71	96.1	83.4
2017/.02	1.84	56.3	1.50	63.3	81.5

Death on 2017/05 because of sudden cardiac arrest after a hypoxemic episode.

Discussion

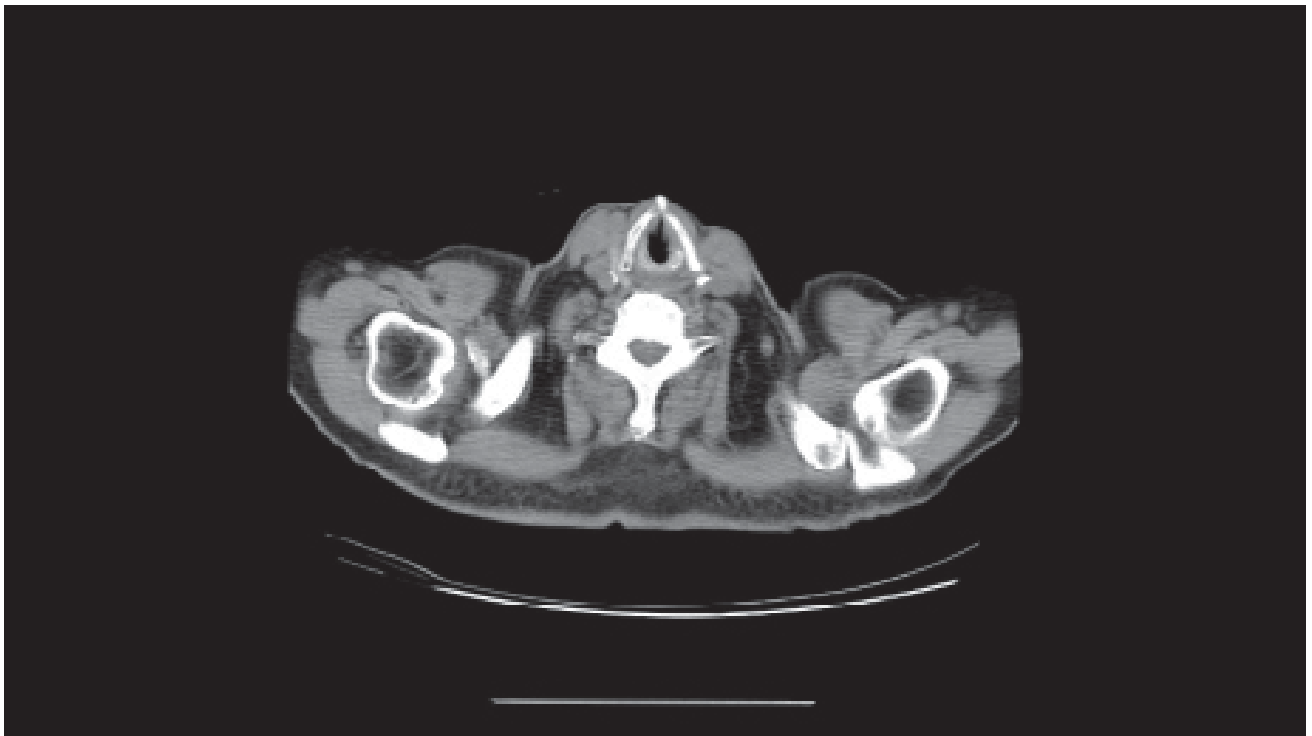
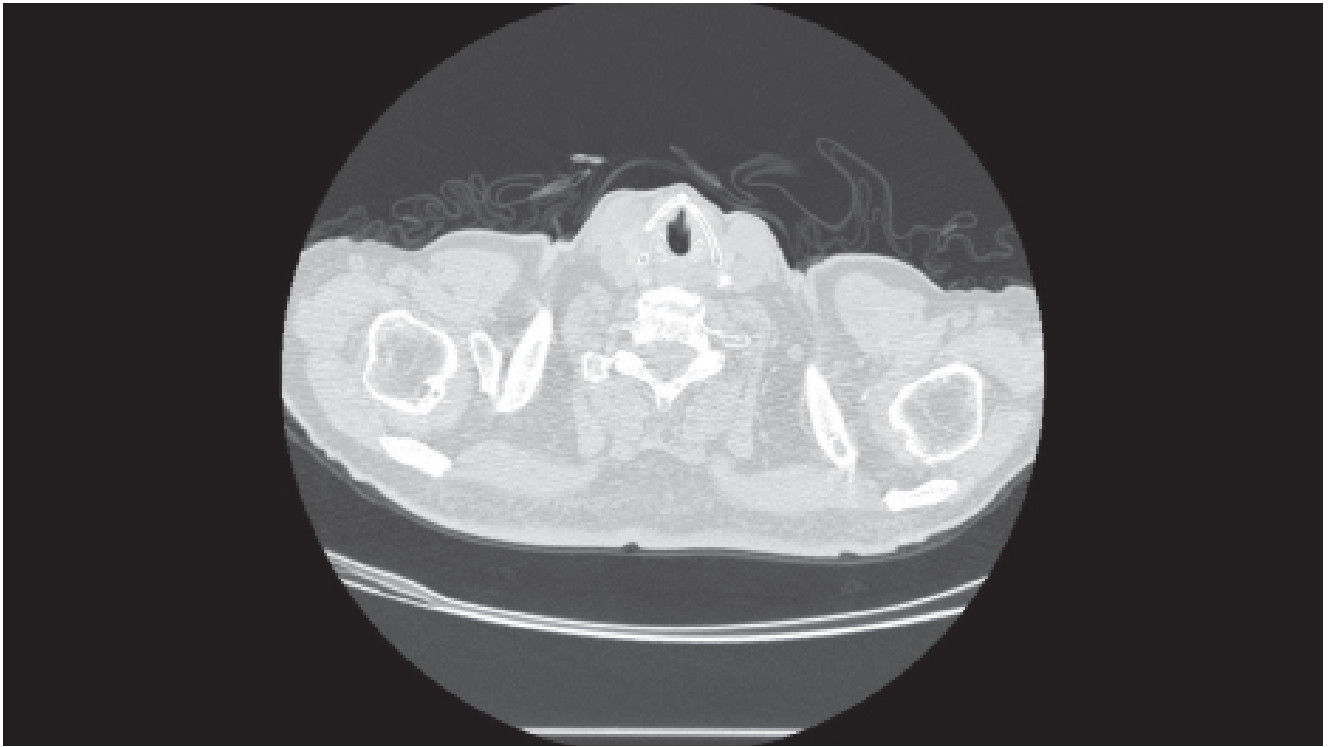
- According to a literature review, there is no well-documented effective treatment for CPFE. Bronchodilators have shown different efficacies in individual cases, depending on the degree of obstruction .
- No studies have individually evaluated the effects of antifibrotic agents on CPFE; however, the ASCEND Trial, which assessed pirfenidone for IPF with emphysema, showed that the medication was well-tolerated and the clinical condition was stable. IPF with emphysema treated with nintedanib in the INPULSIS-1 and INPULSIS-2 studies also reduced the annual decline in FVC. Further clinical trials to determine the effectiveness of antifibrotic agents for CPFE are required.
- Although pulmonary hypertension is common and is a leading cause of death in CPFE patients, specific therapies for pulmonary hypertension therapies, such as endothelin-1 receptor antagonists, prostanoids and phosphodiesterase type 5 inhibitors, have shown no beneficial results in most clinical trials. These drugs may worsen hypoxemia due to vasodilation, which aggravates the ventilation/perfusion mismatch.

Abbreviations

CPFE, combined pulmonary fibrosis and emphysema; ANA, anti-nuclear antibody; BPM, beats per minute; CBC, complete blood count; anti-CENP, anti-centromere proteins antibody; C3, complement component 3; C4, complement component 4; D_{LCO} , diffusion capacity of the lung for carbon monoxide; anti-ENA, anti-extractable nuclear antigen antibody; FEV₁, forced expiratory volume in one second; FEV_{25%-75%}, forced expiratory flow at 25%-75%; FVC, forced vital capacity; HRCT, high-resolution computed tomography; IPF, idiopathic pulmonary fibrosis; RF, rheumatoid factor; TLC, total lung capacity; TRPG, tricuspid regurgitation peak gradient; UIP, usual interstitial pneumonia

References

1. Jankowich MD, Rounds SIS. Combined pulmonary fibrosis and emphysema syndrome: a review. *Chest* 2012;141(1):222-31.
2. Portillo K, Morera J. Combined Pulmonary Fibrosis and Emphysema Syndrome: A New Phenotype within the Spectrum of Smoking-Related Interstitial Lung Disease. *Pulm Med* 2012;2012:867870.
3. Lin H, Jiang S. Combined pulmonary fibrosis and emphysema (CPFE): an entity different from emphysema or pulmonary fibrosis alone. *J Thorac Dis* 2015;7(4):767-79.
4. King TE Jr, Bradford WZ, Castro-Bernardini S, Fagan EA, Glaspole I, Glassberg MK, et al. A phase 3 trial of pirfenidone in patients with idiopathic pulmonary fibrosis. *N Engl J Med* 2014;370(22):2083-92.
5. Richeldi L, du Bois RM, Raghu G, Azuma A, Brown KK, Costabel U, et al. Efficacy and safety of nintedanib in idiopathic pulmonary fibrosis. *N Engl J Med* 2014;370:2071-82.





Asymmetric IPF

Asymmetric distribution of usual interstitial pneumonia pattern in idiopathic pulmonary fibrosis: unusual image of idiopathic pulmonary fibrosis

**Dr. Lih-Yu Chang^a, Dr. Lih-Chyun Chang^b,
Dr. Hao Chien Wang^c**

^aDepartment of Internal Medicine,
National Taiwan University Hospital Hsin-Chu Branch,
Hsin-Chu, Taiwan, ROC

^bDepartment of Internal Medicine,
National Taiwan University Hospital Yun-Lin Branch,
Yun-Lin, Taiwan, ROC

^cDepartment of Internal Medicine,
National Taiwan University Hospital,
Taipei, Taiwan, ROC

Clinical pearls

- An HRCT-defined UIP pattern should be symmetrically distributed; however, if a typical UIP pattern develops unilaterally with a restrictive ventilatory defect and no significant underlying rheumatic diseases, IPF still should be considered.

Patient profile

Case presentation

- 72-year-old man
- Lung fibrosis according to coronary CT images obtained in 2013
- Intermittent dry cough for 6 months that has progressed over the last 2 months
- Decreased exercise tolerance (The maximal swimming distance decreased from 1500 to 500 meters)
- Weight loss of 5 kg

Medical history

- Gout
- Hypertension
- Reflux esophagitis
- Ex-smoker (approximately 6 pack-years); quit 40 years ago
- Unremarkable family history

Physical examination

- Heart rate: 90 bpm
- Mild fine crackles over both lung fields
- No nail clubbing
- No lower extremity edema
- No arthralgias

Laboratory findings

- Normal CBC and biochemistry results
- Negative RF, ANA, anti-SSA/SSB, anti-SCL-70, and anti-CENP antibodies; normal C3 and C4 levels
- Negative bacterial, mycobacterial, and fungal cultures

Pulmonary function test findings

Parameter	Value
FVC	86.7% predicted
FEV ₁	111.4% predicted
FEV ₁ /FVC	98.7%
FEF _{25%-75%}	340% predicted
TLC	78.68% predicted
D _{LCO}	89.68% predicted

Conclusion: Mild restrictive ventilatory defect with a normal diffusion capacity

Cardiac evaluation

Nil

Radiological imaging studies

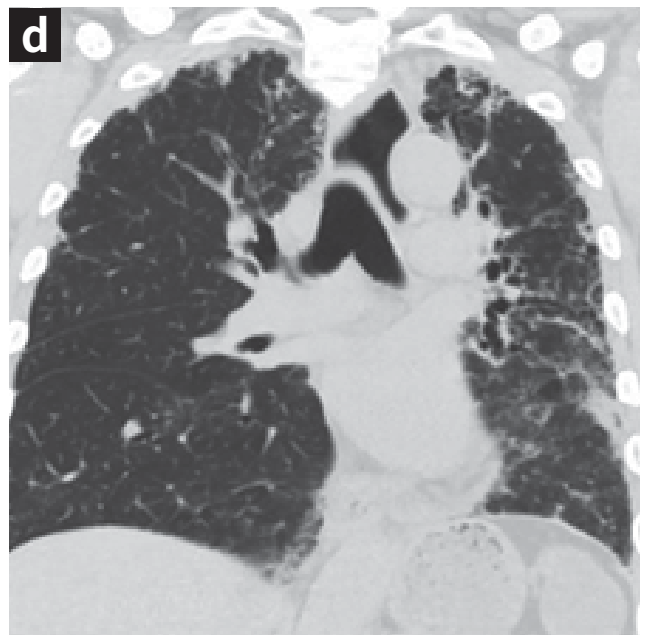
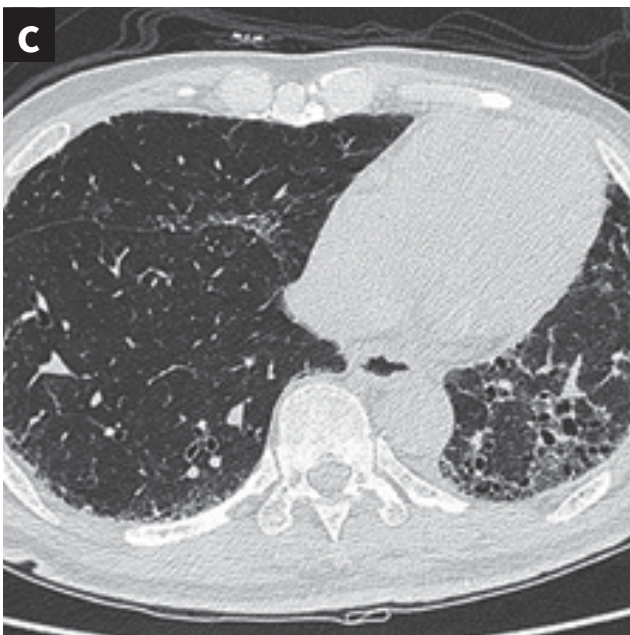
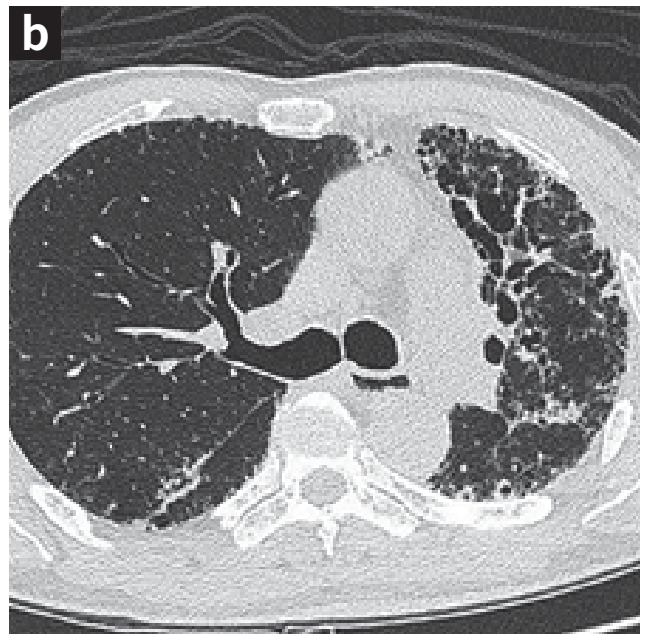
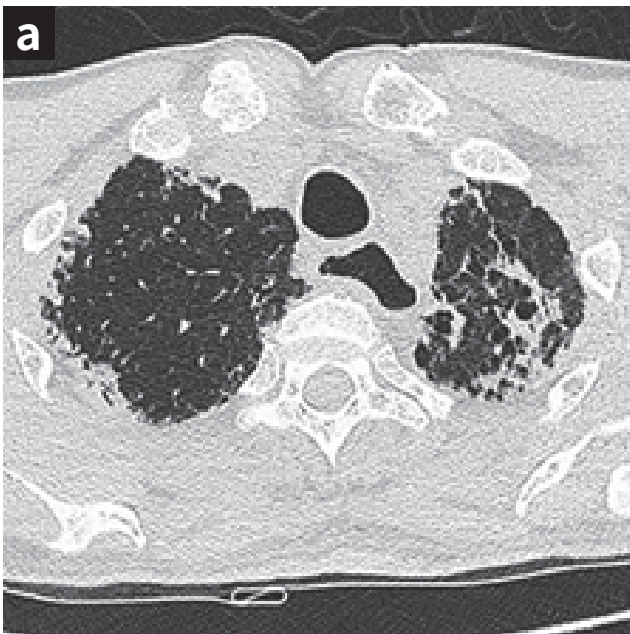
Figure 1: Chest radiography findings

- The PA chest radiograph shows bilateral interstitial infiltration, predominantly at the left lung associated with volume reduction. Milder interstitial opacities of the right lung (Figure 1).
- Left side predominantly
- Combined with pleural thickening and fibrotic changes in the upper and lower lungs.

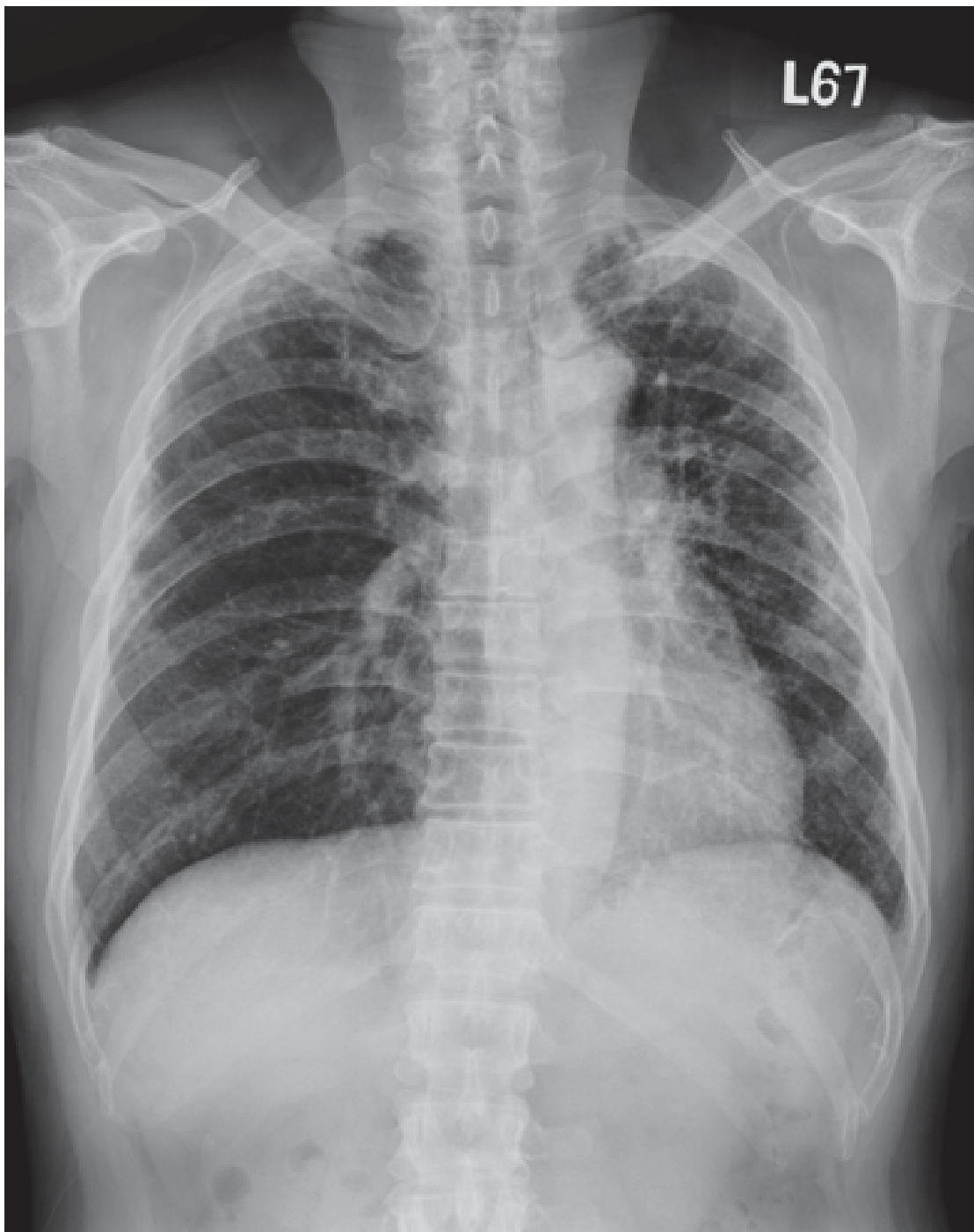

Figure 2a - 2d: HRCT findings

HRCT (1 mm) at the level of apical lung (Figure 2a), carina (Figure 2b) and basal lower lobes (Figure 2c) show subpleural fine reticulation, bronchiectasis, and some honeycombing cysts predominantly at the left lung, associated with mediastinal shifting due to volume loss and lung fibrosis much milder subpleural reticulation of the right lung is found. Similar CT findings on coronal reconstruction image (3 mm collimation) (Figure 2d).



Diagnostic process

- Although chest radiograph showed predominant left lung involvement, the HRCT image revealed a UIP pattern.
- The pulmonary function testing only showed a restrictive ventilatory defect. A decreasing trend was observed for D_{LCO} (from 89.68% to 78.72% of predicted).
- Serological markers for possible related rheumatologic diseases were all negative.
- After excluding other possible causes for granulomatous lung disease, IPF was determined as the most likely cause.

Abbreviations

ANA, anti-nuclear antibody; CBC, complete blood count; anti-CENP, anti-centromere protein antibody; anti-SSA/SSB: anti-Sjögren syndrome-related antigen A/B; anti-SCL-70: anti-topoisomerase I antibody; C3, complement component 3; C4, complement component 4; D_{LCO} , diffusion capacity of the lung for carbon monoxide; anti-ENA, anti-extractable nuclear antigen antibodies; FEV₁, forced expiratory volume in one second; FEF_{25%-75%}, forced expiratory flow at 25%-75%; FVC, forced vital capacity; HRCT, high-resolution computed tomography; IPF, idiopathic pulmonary fibrosis; RF, rheumatoid factor; TLC, total lung capacity; UIP, usual interstitial pneumonia

Reference

Raghu G, Collard HR, Egan JJ, Martinez FJ, Behr J, Brown KK, et al. An Official ATS/ERS/JRS/ALAT Statement: Idiopathic pulmonary fibrosis: Evidence-based guidelines for diagnosis and management. *Am J Respir Crit Care Med* 2011;183:788-824.



IPF with Lung Cancer

Lung cancer in patients with
idiopathic pulmonary fibrosis

Dr. Chia-Hung Chen^{a,b}, Dr. Wu-Huei Hsu^{a,b}

^aDivision of Pulmonary and Critical Care Medicine,
Department of Internal Medicine, China Medical
University Hospital, Taichung, Taiwan

^bSchool of Medicine, China Medical University Hospital,
Taichung, Taiwan

Clinical pearls

- The prevalence of lung cancer among patients with IPF may vary between 4% and 9%. According to a retrospective cohort study, the cumulative incidence of lung cancer among patients with IPF was 3.3% at 1 year, 15.4% at 5 years, and 54.7% at 10 years.
- Occupational and environmental exposure increases the risk of apparent IPF and lung cancer.
- Cigarette smoking contributes to the association of IPF with the lung cancer risk.
- The diffuse inflammatory process of IPF increases the risk of lung cancer.

Patient profile

Case presentation

- 67-year-old man
- A taxi driver who suffered from dyspnea and cough with purulent sputum since 1 month.

Medical history

- Hypertension treated with amlodipine (5 mg four times a day)
- Smoking history: 1 pack per day for >40 years
- No history of alcohol use
- No pets
- Unremarkable family history

Physical examination

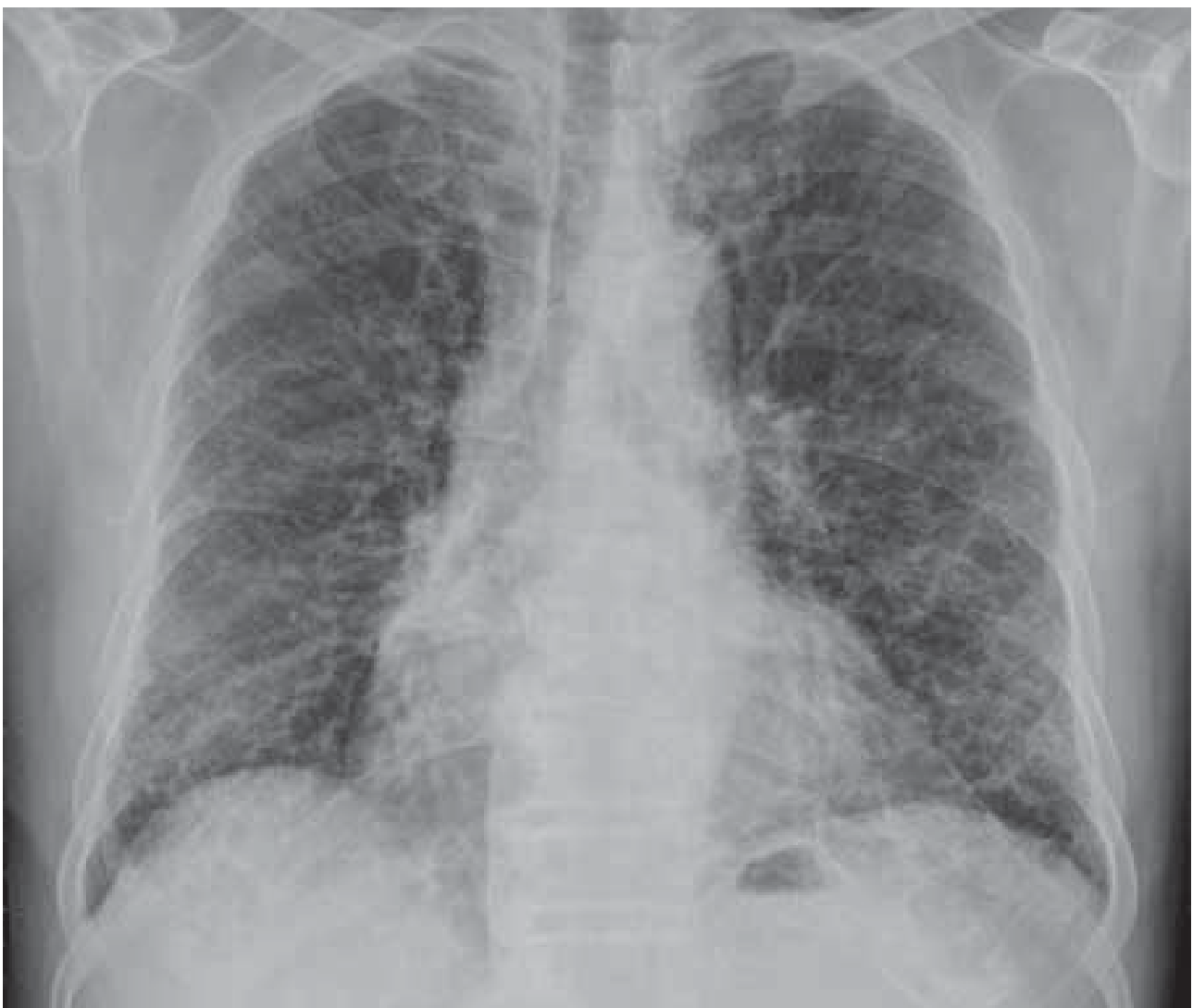- Heart rate: 95 bpm
- SpO₂: 91% on ambient air
- Dry crackles over both lung fields, without an upper lower difference
- Nail Clubbing
- No lower extremity edema
- No arthralgias

Laboratory findings

- Normal CBC and biochemistry results
- RF, ANA, anti-ENA, and anti-CENP negativity; normal C3 and C4 levels
- Negative bacterial, mycobacterial, and fungal cultures

Figure 1: Chest radiography findings

Reticular infiltrates are equally distributed in both lungs, although they are more in the lung periphery. There is no apparent upper-lower lung difference.



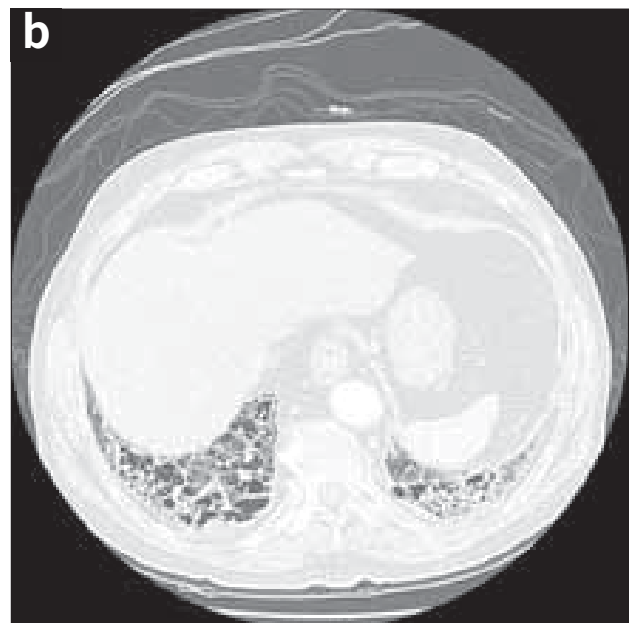
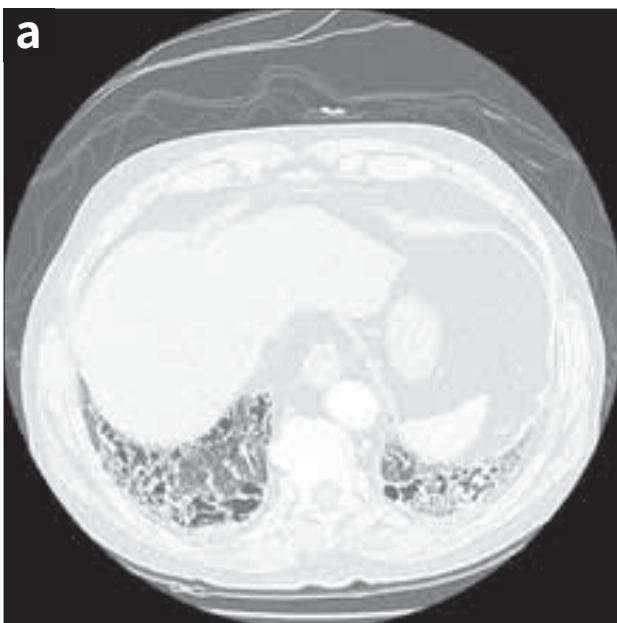
Pulmonary function test finding

Parameter	Value
FVC	55.5% predicted
FEV ₁	54.0% predicted
FEV ₁ /FVC	74.2%
FEF _{25%-75%}	33.8% predicted
TLC	67.4% predicted
D _{LCO}	58.1% predicted

Conclusion: Moderate decrease in TLC and D_{LCO}; mixed obstructive and restrictive ventilatory impairment

Figure 2: HRCT findings

(a) Possible UIP pattern with subpleural, basal predominance, and reticular abnormalities, (b) Emphysematous change and traction bronchiectasis. Diagnostic process and initial treatment

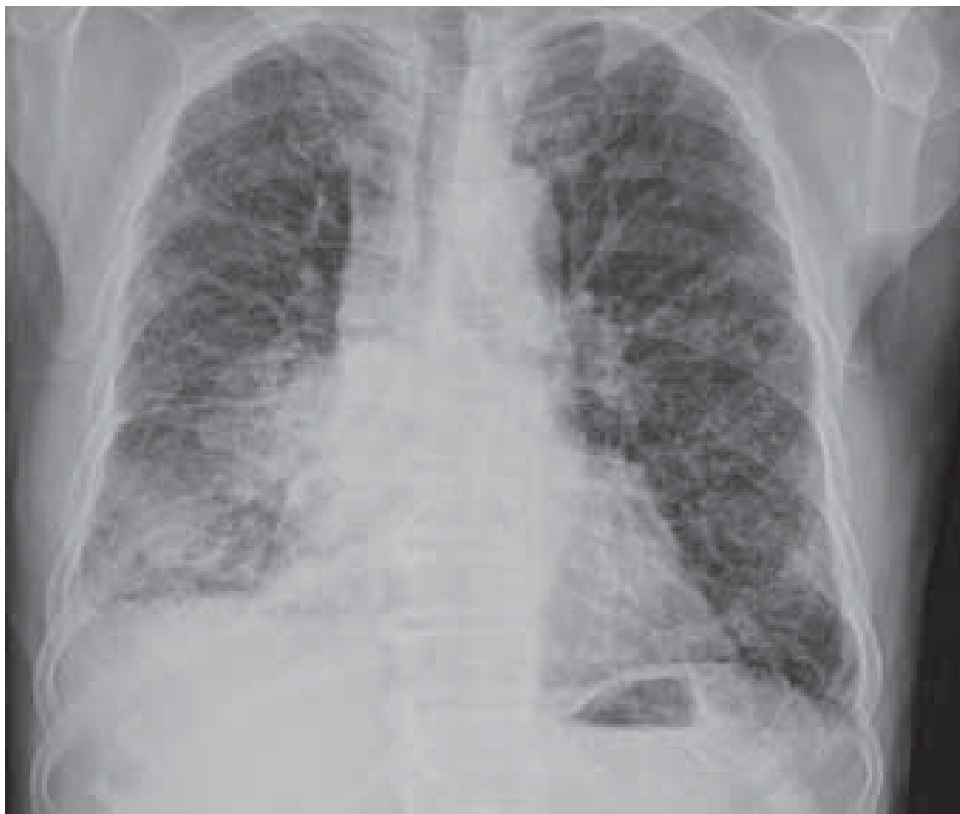

- For a patient with a low clinical risk, negative rheumatologic panels and an HRCT-possible UIP pattern are suggested to establish a diagnosis of IPF.
- Symptomatic treatment

Follow-up

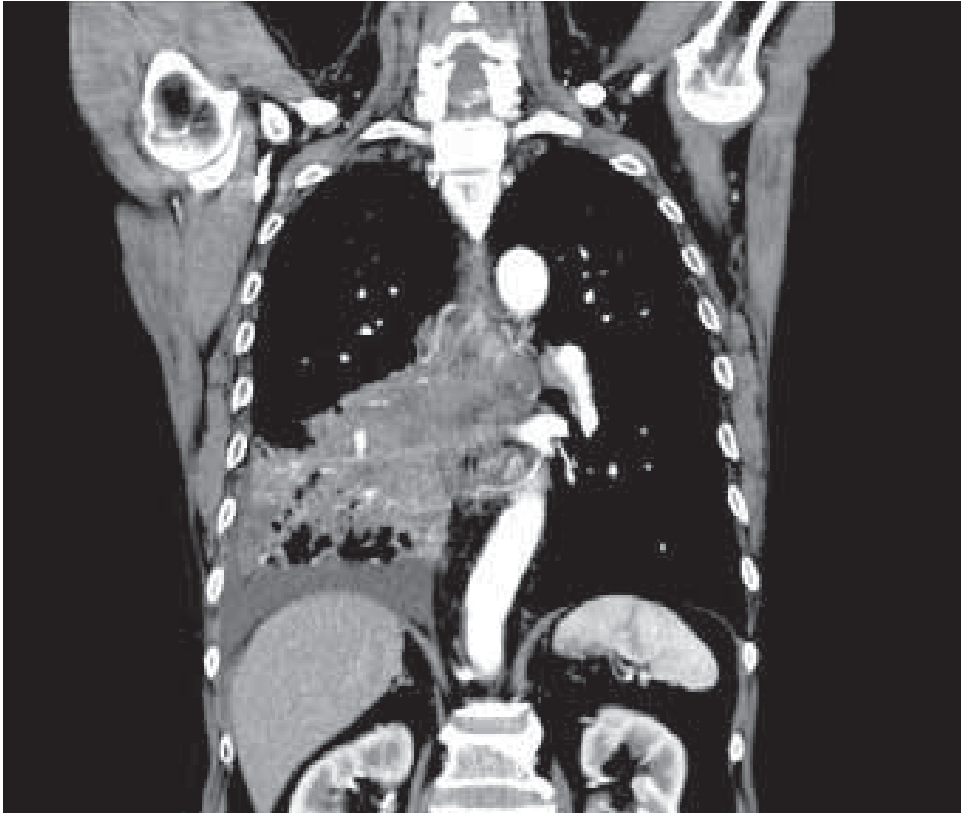
- Lost to follow-up for 2 years
- Returned to the OPD with more severe dyspnea and body weight loss of 3 kg in 6 months

Figure 3: Chest radiography findings



Newly developed opacity and suspected pleural effusion in RLL.

Figure 4: Chest CT findings



Suspected tumor involving RLL

Diagnostic process and further treatment

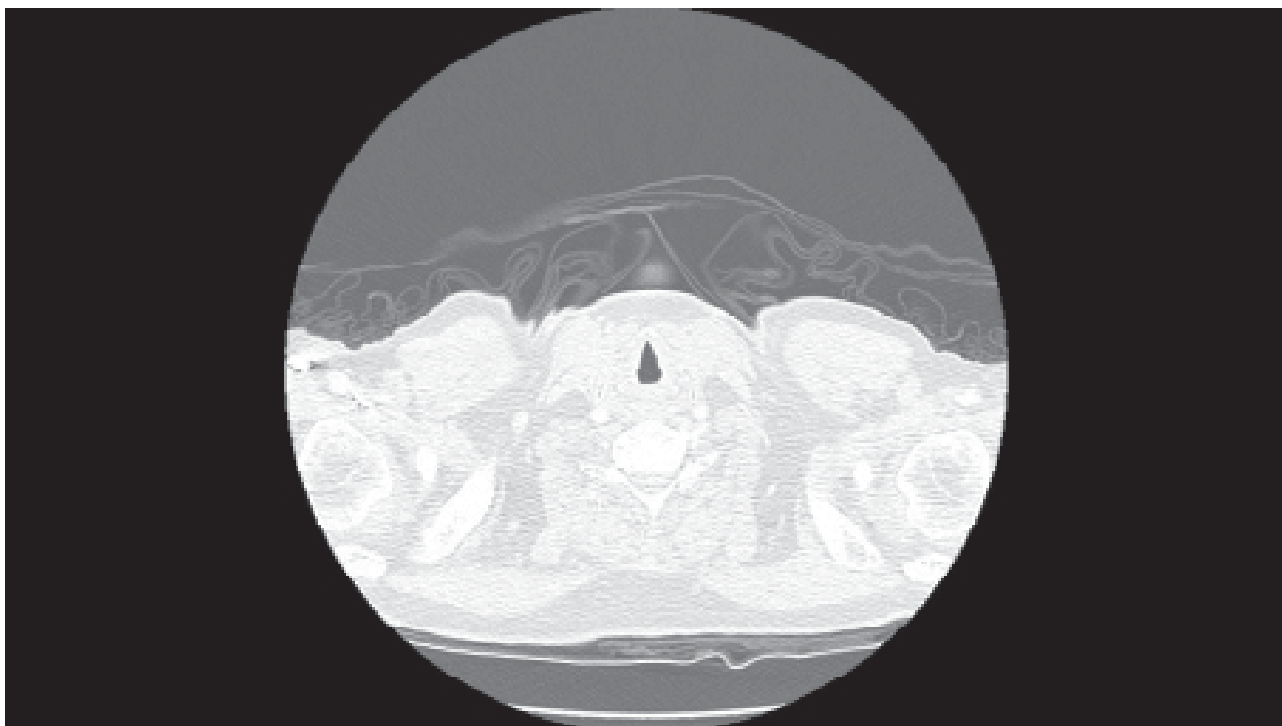
- Newly developed lung opacity in the right lower lobe
- Newly developed pleural effusion in the right lung
- Bronchoscopy with endobronchial ultrasound (EBUS) to RB8 and pathological evaluation revealed adenocarcinoma
- Cytology pleural effusion fluid confirmed adenocarcinoma
- Diagnosis revised to stage IV lung cancer adenocarcinoma due to malignant pleural effusion
- EGFR absent
- Chemotherapy prescribed

Abbreviations

ANA, anti-nuclear antibody; BPM, beats per minute; CBC, complete blood count; anti-CENP, anti-centromere protein antibody; C3, complement component 3; C4, complement component 4; D_{LCO} , diffusion capacity of the lung for carbon monoxide; anti-ENA, anti-extractable nuclear antigen antibody; FEV₁, forced expiratory volume in one second; FEV_{25%-75%}, forced expiratory flow at 25%-75%; FVC, forced vital capacity; HP, hypersensitivity pneumonitis; HRCT, high-resolution computed tomography; IPF, idiopathic pulmonary fibrosis; RF, rheumatoid factor; TLC, total lung capacity; TRPG, tricuspid regurgitation peak gradient; UIP, usual interstitial pneumonia; VATS, video-assisted thoracic surgery

References

1. Hubbard R, Venn A, Lewis S, Britton J. Lung cancer and cryptogenic fibrosing alveolitis. A population-based cohort study. *Am J Respir Crit Care Med* 2000;161(1):5-8.
2. Turner-Warwick M, Lebowitz M, Burrows B, Johnson A. Cryptogenic fibrosing alveolitis and lung cancer. *Thorax* 1980;35(7):496-9.
3. Harris JM, Johnston ID, Rudd R, Taylor AJ, Cullinan P. Cryptogenic fibrosing alveolitis and lung cancer: The BTS study. *Thorax* 2010;65(1):70-6.
4. Ozawa Y, Suda T, Natio T, Enomoto N, Hashimoto D, Fujisawa T, et al. Cumulative incidence and predictive factors for lung cancer in IPF. *Respirology* 2009;14(5):723-8.



II. Differential diagnosis of IPF



Radiological diagnosis of IPF

The diagnosis of IPF often requires a multi-disciplinary approach involving a pulmonologist, radiologist, and pathologist (and occasionally a rheumatologist) experienced in the diagnosis of interstitial lung disease. A pattern indicating of usual interstitial pneumonia on HRCT or in the analysis of lung specimens obtained by surgical lung biopsy is crucial for the final diagnosis.

For the diagnosis of IPF conditions such as fibrotic nonspecific interstitial pneumonia (NSIP); other forms of idiopathic interstitial pneumonia; and interstitial lung diseases associated with occupational or environmental exposure, systemic disease, or drugs need to be excluded.

In this section, we describe three cases with different conditions that mimic IPF, including chronic hypersensitivity pneumonitis (CHP), drug-induced lung fibrosis, and NSIP due to Sjögren syndrome. We hope that the readers will find these case descriptions helpful in their daily practice.



End-stage CHP

A case of chronic hypersensitivity pneumonitis caused by exposure to old bank notes

Dr. Yueh-Feng Wen^a, Dr. Ping-Hung Kuo^b

^aDepartment of Internal Medicine,
National Taiwan University Hospital Hsin-Chu Branch,
Hsin-Chu, Taiwan

^bDepartment of Internal Medicine,
National Taiwan University Hospital, and College of Medicine,
Taipei, Taiwan

Clinical pearls

- Hypersensitivity pneumonitis (HP) is an immune-mediated interstitial lung disease caused by recurrent exposure to triggers in genetically-susceptible individuals.
- Chronic HP (CHP) is often misdiagnosed as idiopathic pulmonary fibrosis (IPF) or other interstitial lung diseases if the history of exposure is unclear and the findings of diagnostic studies are not conclusive.
- The diagnosis of HP may be challenging because of the lack of a gold standard. It requires integrated data pertaining to clinical and radiological features, the exposure history, serum precipitin levels, bronchoalveolar lavage findings, and histopathological findings.
- The need for identification of the offending antigen is crucial, not only for diagnosis and management, but also for assessment of the prognosis.
- Further investigations are warranted to determine the epidemiology, pathogenesis, genetic susceptibility, and validation of the proposed diagnostic criteria for HP.

Patient profile

Case presentation

- A 29-year-old man working at a bank and handling old bank notes for 4 years
- Chief complaints: dry cough and dyspnea on exertion for 3 years, particularly during working days
- Weight loss of 9 kg over 3 years

Personal history

- Non-smoker
- Pectus excavatum since birth
- Unremarkable medical and family histories
- No other exposure history

Physical examination

- Heart rate: 117 bpm; no murmurs
- SpO₂: 94% on ambient air
- Lungs: coarse breath sounds with fine crackles over the bilateral upper and lower lung fields
- No nail clubbing
- No lower extremity edema

Laboratory findings

- Normal CBC and biochemistry results
- RF, ANA, anti-ENA, and anti-CENP negativity; normal C3 and C4 levels
- Sputum: negative bacterial, mycobacterial, and fungal cultures

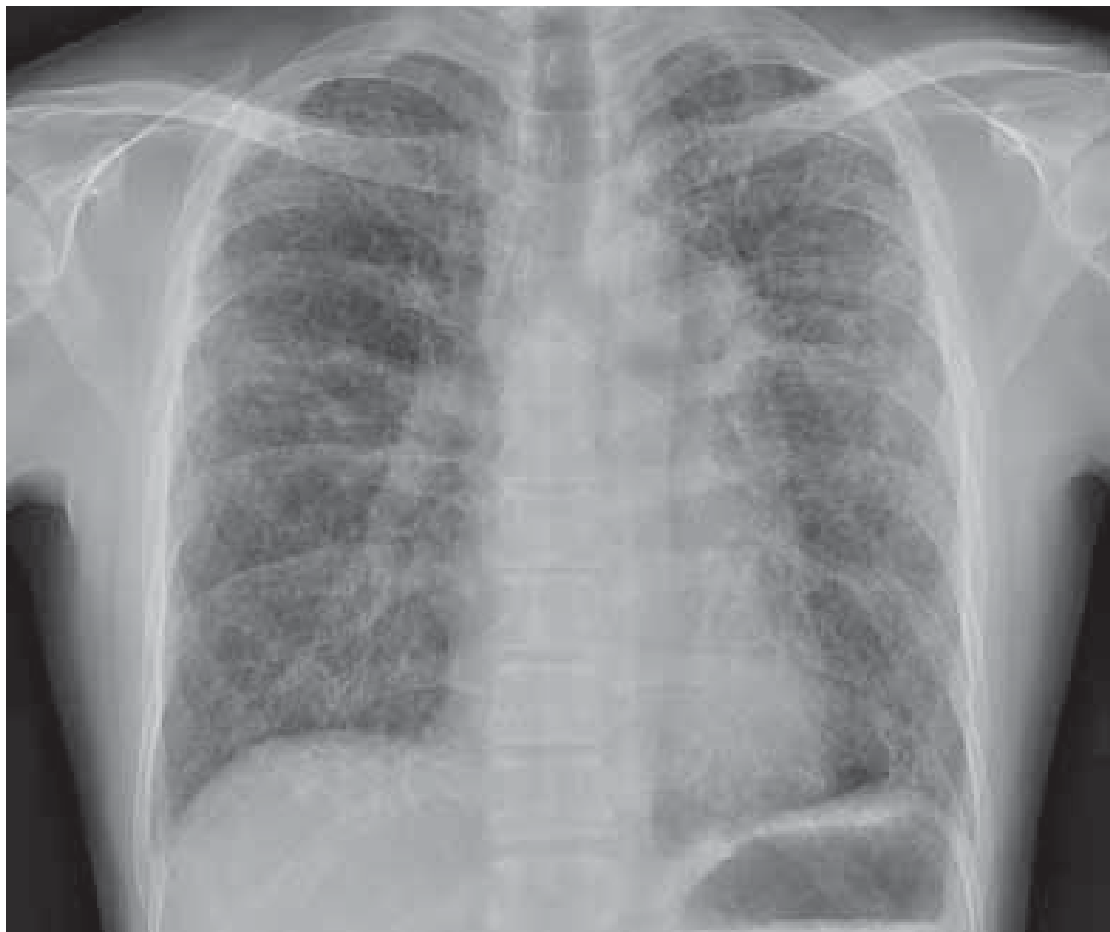Pulmonary function test findings

Parameter	Value
FVC	54.6% predicted
FEV ₁	60.6% predicted
FEV ₁ /FVC	97.8%
FEF _{25%-75%}	94.0% predicted
TLC	59.2% predicted
D _{LCO}	23.9% predicted

Conclusion: Moderate restrictive ventilatory defect and severe impairment in the diffusion capacity.

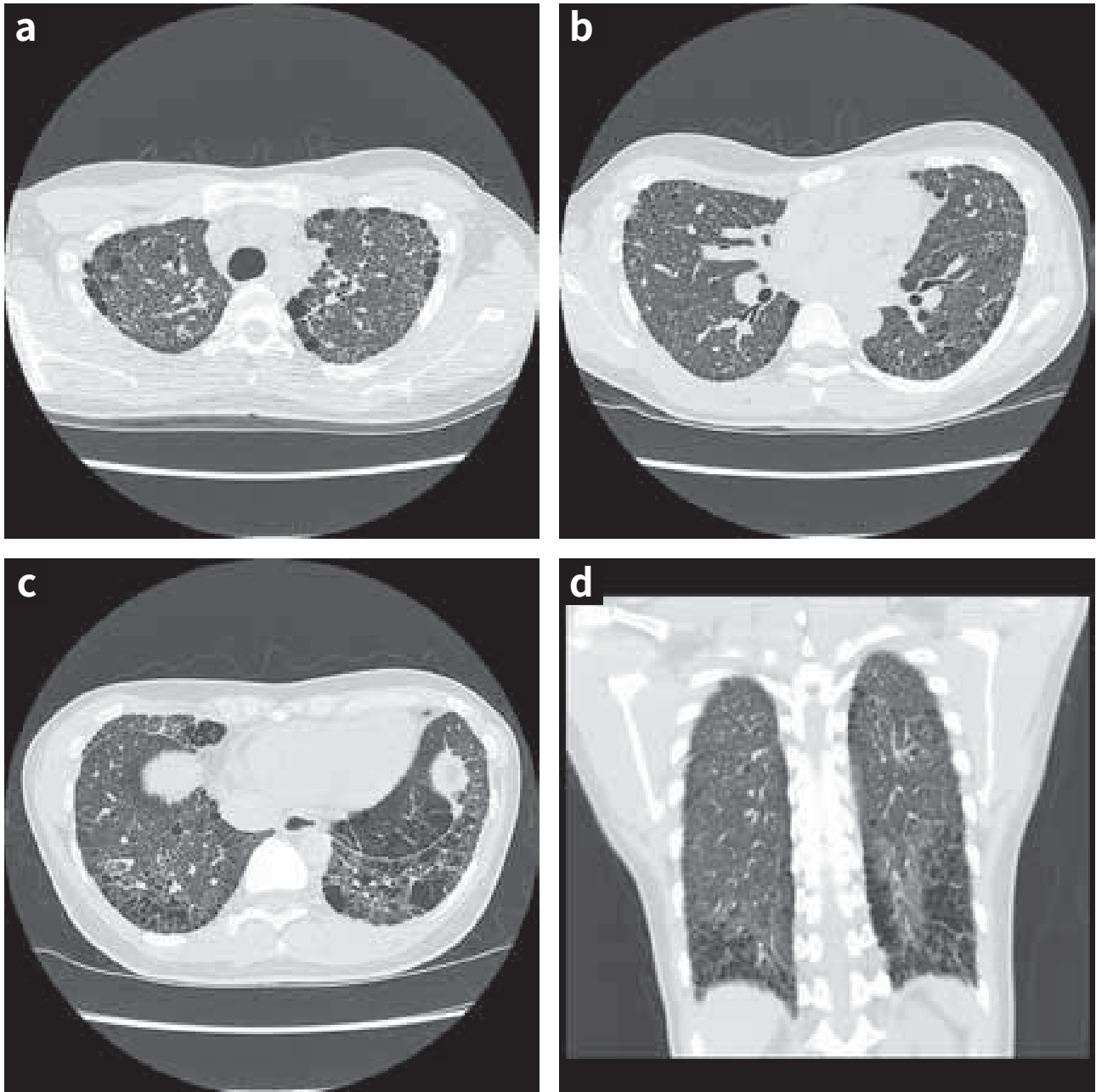
Radiological imaging studies

Figure 1: Chest radiography findings



Normal heart size, dilated pulmonary trunk and diffuse bilateral interstitial infiltrations.

Figure 2a-2d: HRCT findings



HRCT images of the chest at apical region (Figure 2a), mid lung (Figure 2b), and basal lower lungs (Figure 2c), show homogenous distribution of reticulation. These are some cystic lung panenchymal change with preserved core structure, especially at the lower lobes, and paraseptal emphysema (Figure 2c, 2d).

Some scattered micronodules are noted.

Figure 3a-3b: Findings of lung biopsy performed via VATS

Figure 3a (x40)

Interstitial fibrosis with focal lymphoid aggregation (*thick arrow*) alternating with normal lung parenchyma (*thin arrow*), without typical honeycomb spaces, can be seen. Multiple fibroblastic foci are also visible (*asterisk*).

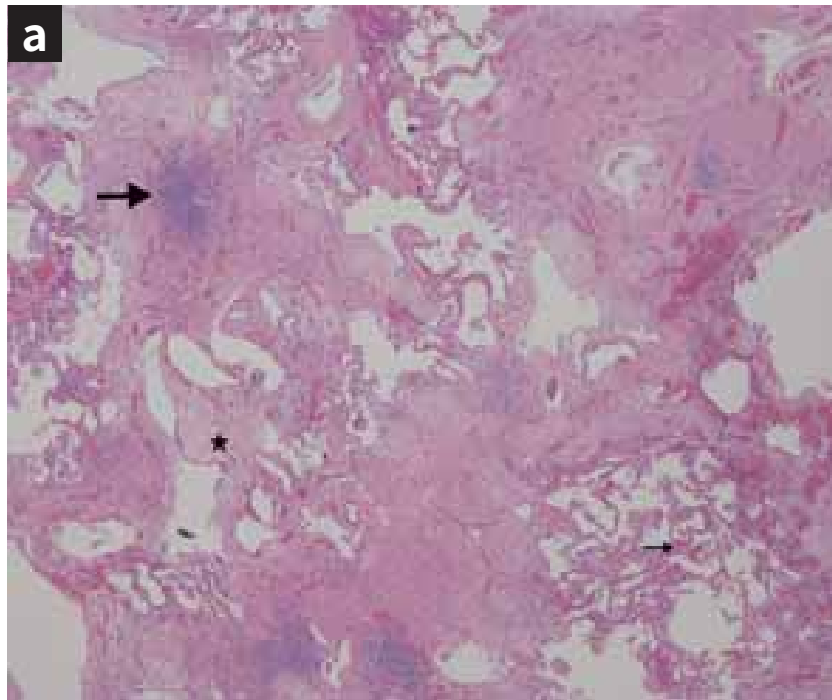
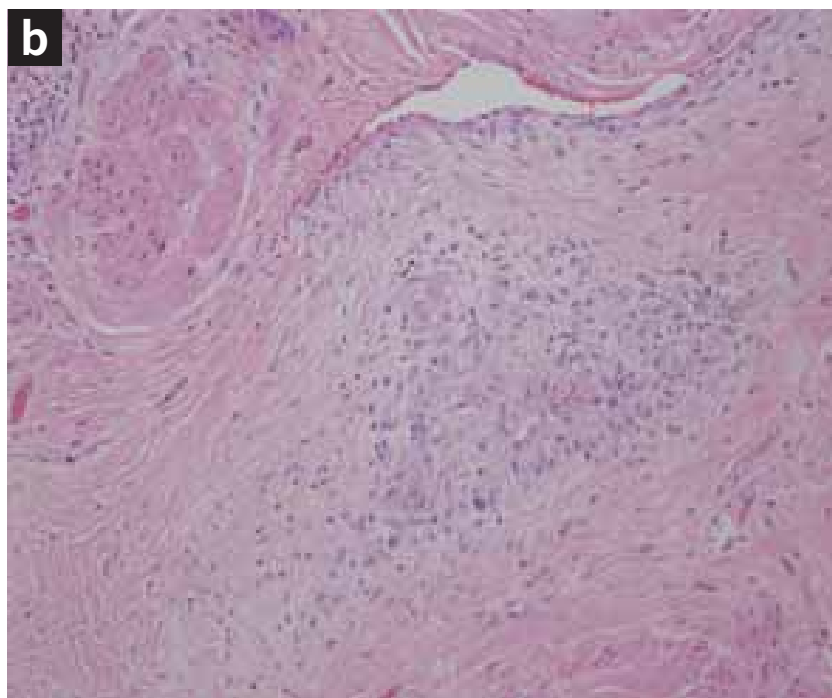


Figure 3b (x200)

The image shows non-caseating granulomatous inflammation.



Discussion

- In the present case, recurring symptoms at the workplace, inspiratory crackles on examination, and weight loss raised a suspicion of CHP, on the basis of a clinical prediction model proposed by Lacasse et al.
- The typical HRCT findings of CHP include intralobular and interlobular septal thickening, traction bronchiectasis, and honeycombing with a mid-to-upper lung zone predominance. Therefore, if evidence of active diseases such as fluffy centrilobular nodules and GGOs is absent, CHP may mimic other fibrotic IIPs with regard to HRCT findings.
- In patients with UIP patterns on HRCT, a cut-off value of 40% for lymphocytes in BAL fluid has been shown to be effective in distinguishing CHP from IPF.
- Precise differentiation between CHP, IPF, and other fibrotic IIPs may be challenging if the offending antigen remains inconclusive after detailed history taking and exhausting accessible laboratory diagnostic tests. A lung biopsy is often required to revise the diagnosis and subsequent treatment strategy, as required for the present case.
- TBB or lung biopsy performed via VATS may indicate the diagnostic features of CHP, particularly in the presence of lymphocytes in BAL. The diagnostic value of transbronchial cryobiopsy for CHP remains unclear.
- The classical histopathological findings for CHP usually include patchy fibrosis with sub-pleural/paraseptal distribution, fibroblastic foci, and honeycombing. Discriminative features, such as centrilobular fibrosis/inflammation, lymphoid/plasmacytic infiltration, and poorly formed granulomas, are often evident and crucial for establishing a diagnosis of CHP. However, these findings may be easily overlooked.
- Although it cannot be confirmed, repetitive exposure to old and dirty bank notes was the most likely cause for CHP in this case. A similar case has been reported in the literature.

Acknowledgement

We thank Dr. Min-Shu Hsieh for the proofreading assistance.

Abbreviations

ANA, anti-nuclear antibody; BAL, bronchoalveolar lavage; BPM, beats per minute; CBC, complete blood count; anti-CENP, anti-centromere protein antibody; C3, complement component 3; C4, complement component 4; CHP, chronic hypersensitivity pneumonitis; D_{LCO} , diffusion capacity of the lung for carbon monoxide; anti-ENA, anti-extractable nuclear antigen antibody; FEV_{1s} , forced expiratory volume in one second; $FEF_{25\%-75\%}$, forced expiratory flow at 25%-75%; FVC, forced vital capacity; GGO, ground glass opacity; HP, hypersensitivity pneumonitis; HRCT, high-resolution computed tomography; IIP, idiopathic interstitial pneumonia; IPF, idiopathic pulmonary fibrosis; RF, rheumatoid factor; TBB, transbronchial biopsy; TLC, total lung capacity; TRPG, tricuspid regurgitation peak gradient; UIP, usual interstitial pneumonia; VATS, video-assisted thoracic surgery

References

1. Spagnolo P, Rossi G, Cavazza A, Bonifazi M, Paladini I, Bonella F, et al. Hypersensitivity pneumonitis: a comprehensive review. *J Investig Allergol Clin Immunol* 2015;25(4):237-250.
2. Hodnett PA, Naidich DP. Fibrosing interstitial lung disease. A practical high-resolution computed tomography-based approach to diagnosis and management and a review of the literature. *Am J Respir Crit Care Med* 2013;188(2):141-149.
3. Lacasse Y, Selman M, Costabel U, Dalphin JC, Ando M, Morell F, et al. Clinical diagnosis of hypersensitivity pneumonitis. *Am J Respir Crit Care Med* 2003;168(8):952-958.
4. Ohshimo S, Bonella F, Cui A, Beume M, Kohno N, Guzman J, et al. Significance of bronchoalveolar lavage for the diagnosis of idiopathic pulmonary fibrosis. *Am J Respir Crit Care Med* 2009(11);179:1043-1047.
5. Ohshimo S, Guzman J, Costabel U, Bonella F. Differential diagnosis of granulomatous lung disease: clues and pitfalls. *Eur Respir Rev* 2017; 26(145). pii: 170012. doi: 10.1183/16000617.0012-2017.
6. Kupeli E, Karnak D, Sak SD, Kayacan O. Hazards of the 'hard cash': hypersensitivity pneumonitis. *Can Respir J* 2010;17(5):e102-5.



Drug-induced interstitial lung disease

**Interstitial pneumonitis after
treatment with pemetrexed in a
patient with non-small cell lung
cancer**

Dr. Ching-Lung Liu

Chest Division,
Department of Internal Medicine,
MacKay Memorial Hospital
Taipei, Taiwan

Clinical pearls

Drug-induced interstitial lung disease (DILD) is relatively rare. A diagnosis is usually established when a patient with interstitial lung disease (ILD) is exposed to a medication known to result in lung disease and, most importantly, after the exclusion of other causes of lung damage.

Patient profile

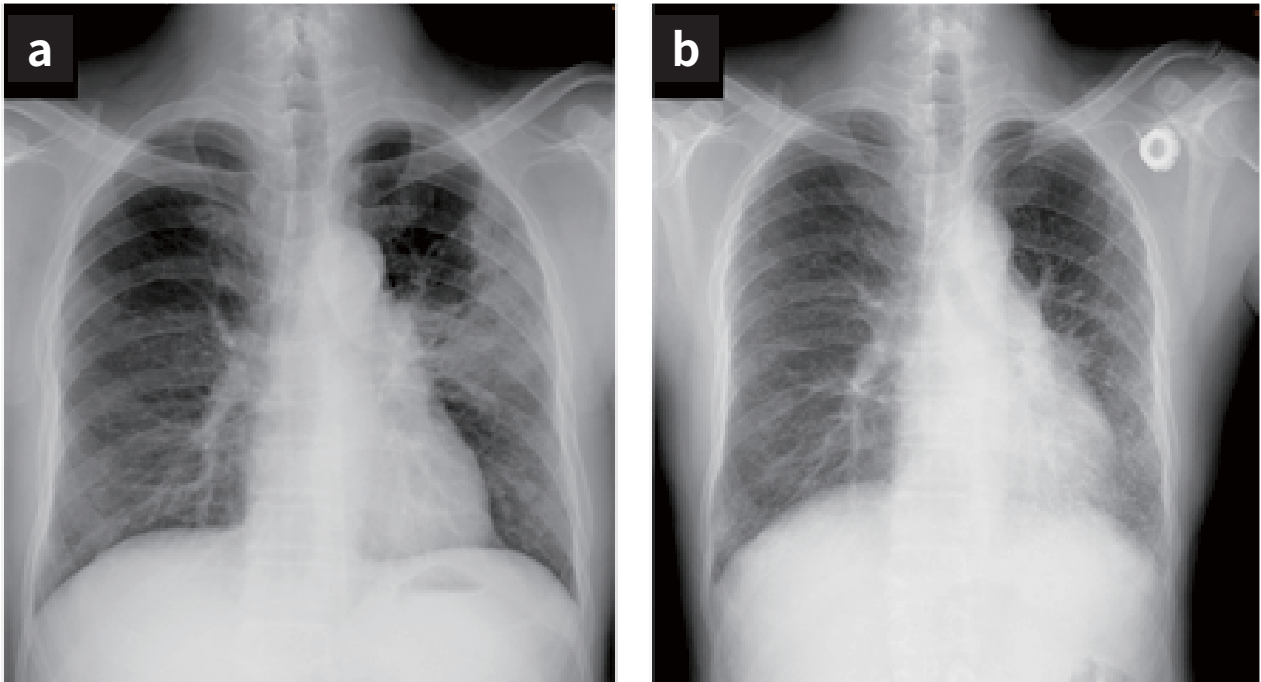
Case presentation

A 57-year-old man with a (previous smoking history of 36 pack-years), was diagnosed with metastatic adenocarcinoma of the lung (cT2N0M1, stage IV). Because of a good general condition (ECOG PS 0), five cycles of chemotherapy with pemetrexed plus cisplatin were initiated. Chest CT revealed a significant decrease in tumor size, and a partial response was recorded. Subsequently, the patient began pemetrexed maintenance therapy (500 mg/m² every 21 days) and was prescribed folic acid to avoid pemetrexed-related toxicities. He continued chemotherapy for 16 additional cycles, with no evidence of disease progression 17 months after diagnosis. Unfortunately, he experienced a dry cough and worsening dyspnea.

Laboratory findings

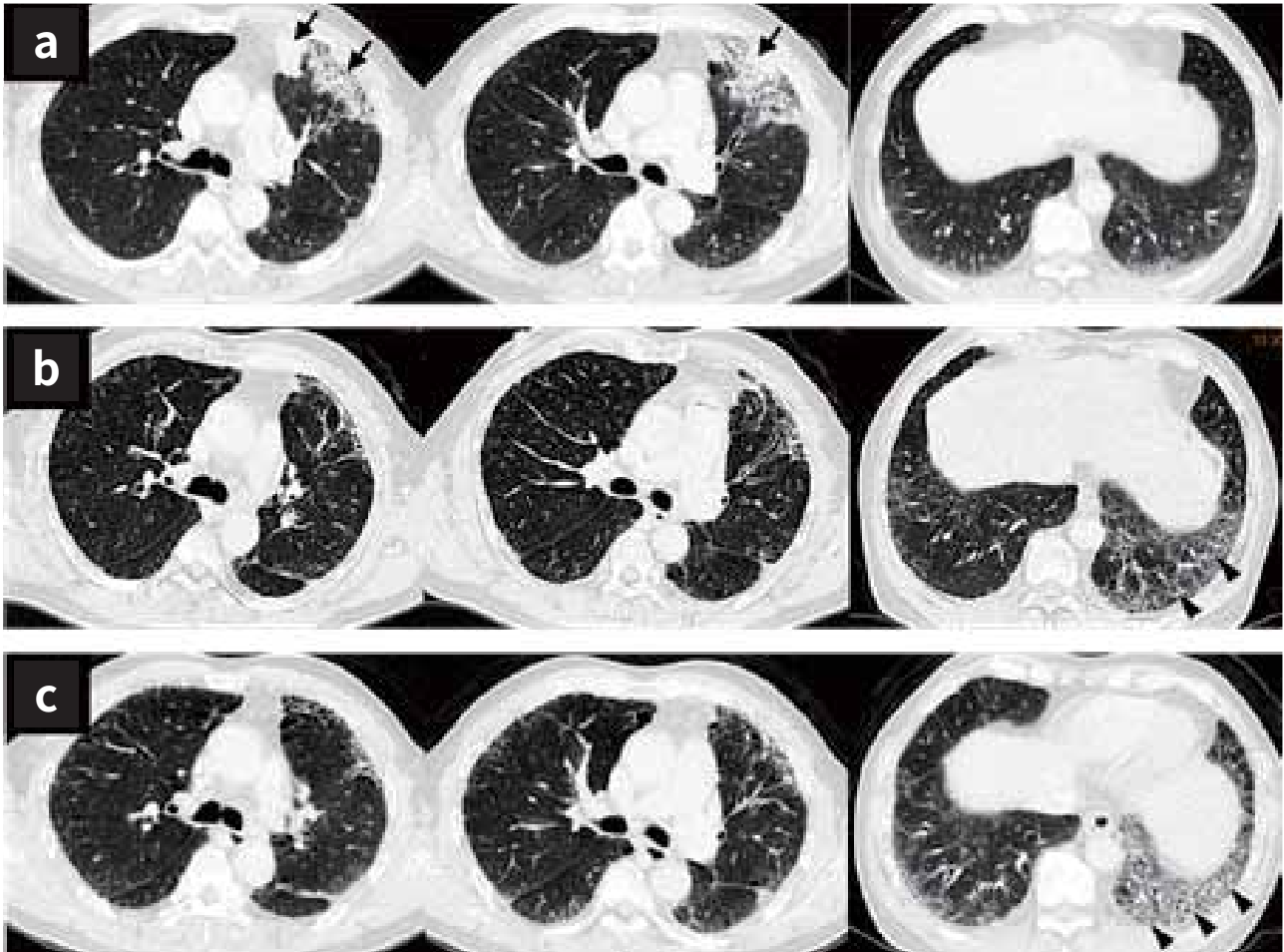
- Normal CBC results
- ANA, RF, anti-ENA (SSA), anti-ENA (SSB), and anti-ENA (Sc170) negativity

Figure 1a-1b: Chest radiography findings



(a) A chest radiograph obtained the time of lung adenocarcinoma diagnosis shows an ill-defined area of increased density in the upper left lobe without volume loss. (b) After diagnosis and 17 months of maintenance chemotherapy, hazy reticular infiltrates can be seen in the middle and lower lung fields.

Figure 2a-2c: Chest CT findings

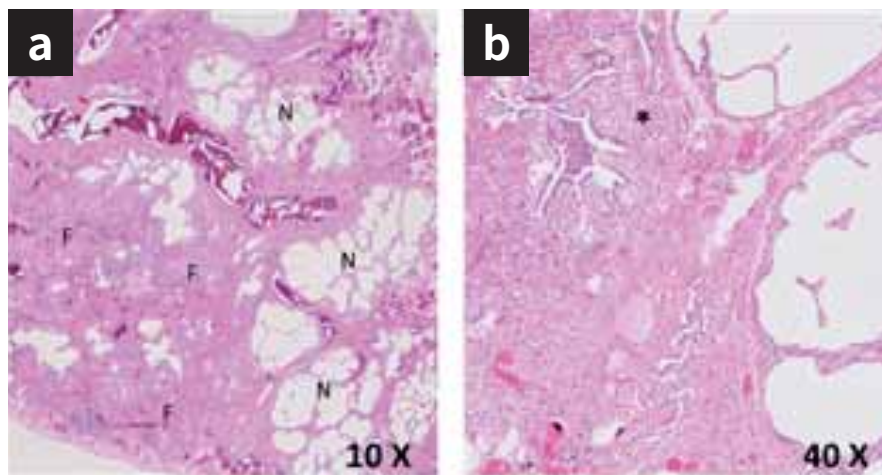


(a) Chest CT performed at the time of lung cancer diagnosis, demonstrates extensive ground glass opacities mixed with consolidation (arrow) in the peripheral parenchyma of the anterior segment of the upper left lobe. (b) After diagnosis and 4 months of maintenance chemotherapy. (c) After 17 months of maintenance chemotherapy, areas of progressive ground-glass opacities mixed with reticular fibrosis and honeycombing (arrowhead) can be seen.

Pulmonary function test findings

Parameter	Value	
	Before chemotherapy	At 17 months after diagnosis and chemotherapy
FVC	111% predicted	86% predicted
FEV ₁	103% predicted	84% predicted
FEV ₁ /FVC	75%	79%
FEF _{25%-75%}	76% predicted	79% predicted
TLC	115% predicted	89% predicted
D _{LCO}	91% predicted	59% predicted
Interpretation	Normal	Normal-to-mild restrictive pattern and significantly decreased diffusion capacity

Figure 3a-3b: Microscopic findings in lung biopsy specimens obtained via VATS



(a) Lung tissue with interstitial fibrosis adjacent to relatively normal lung parenchyma (F=fibrosis, N=normal lung.) can be seen. (b) Areas of fibrosis adjacent to areas of fibroblastic foci (*) are also observed. The pathological features are consistent with those for a UIP pattern.

Discussion

Interstitial pneumonitis induced by a drug is a rare but potentially fatal complication. DILD can be caused by chemotherapeutic agents (e.g., bleomycin and cyclophosphamide), antibiotics (e.g., amphotericin B and minocycline), anti-arrhythmic drugs (e.g., amiodarone), and immunosuppressives agents (e.g., NSAIDs, gold, penicillamine, azathioprine, and methotrexate). There are no distinct physiologic, radiological, or pathological patterns for DILD, and a diagnosis is usually established when a patient with ILD is exposed to a drug known to result in lung disease and, most importantly, after the exclusion of other causes of lung damage. Early withdrawal of the offending drug and/or judicious treatment with steroids can might lead to amelioration or resolution of the drug-induced lung injury.

Abbreviations

ANA, anti-nuclear antibody; anti-ENA, anti-extractable nuclear antigen antibody; CBC, complete blood cell count; CT, computed tomography; DILD, drug-induced interstitial lung disease; $D_{L_{CO}}$, diffusion capacity of the lung for carbon monoxide; FEV₁, forced expiratory volume in one second; FEF_{25%-75%}, forced expiratory flow at 25%-75%; FVC, forced vital capacity; ILD, interstitial lung disease; NSAID, nonsteroidal anti-inflammatory drug; RF, rheumatoid factor; TLC, total lung capacity; UIP, usual interstitial pneumonia; VATS, video-assisted thoracoscopic surgery

References

1. Kim KH, Song SY, Lim KH, Han SS, Kim SH, Cho JH, et al. Interstitial pneumonitis after treatment with pemetrexed for non-small cell lung cancer. *Cancer Res Treat* 2013;45(1):74-77.
2. Kato M, Shukuya T, Takahashi F, Mori K, Suina K, Asao T, et al. Pemetrexed for advanced non-small cell lung cancer patients with interstitial lung disease. *BMC Cancer* 2014;14:508.
3. Dhakal B, Singh V, Shrestha A, Rao A, Choong N. Pemetrexed-induced pneumonitis. *Clin Pract* 2011;1(4):e106.
4. Schwaiblmair M, Behr W, Haeckel T, Märkl B, Foerg W, Berghaus T. Drug induced interstitial lung disease. *Open Respir Med J* 2012;6:63-74.



NSIP (Sjögren's syndrome)

Connective tissue
disease-associated interstitial
lung disease

Dr.Chau-Chyun Sheu

Division of Pulmonary and Critical Care Medicine,
Kaohsiung Medical University Hospital,
Kaohsiung, Taiwan

Clinical pearls

- Connective tissue diseases (CTDs) are common causes of interstitial lung diseases (ILDs,); therefore, affected patient should be routinely screened.
- Typical HRCT findings for non-specific interstitial pneumonia (NSIP) include bilateral basal-predominant ground-glass opacities with a peribronchovascular distribution with or without sub-pleural sparing. Reticulation and traction bronchiectasis can be observed in patients with fibrotic NSIP. Honeycombing is rare.
- Mixed connective tissue disease, systemic sclerosis, rheumatoid arthritis, polymyositis/dermatomyositis, Sjögren's syndrome, and systemic lupus erythematosus are CTDs commonly exhibiting pulmonary involvement.
- Up to 20% patients with Sjögren's syndrome develop ILD. The onset of ILD is typically 5-10 years after the onset of Sjögren's syndrome. NSIP is the most common form, followed by lymphocytic interstitial pneumonia (LIP) and usual interstitial pneumonia (UIP).
- Treatment should be considered for severe or progressive CTD-ILD, with corticosteroids being the first line of drugs. The efficacy and safety of new antifibrotic medications (nintedanib and pirfenidone) for CTD-ILD are now being investigated.

Patient profile

Case presentation

- 62-year-old woman
- Dry cough for 1 year
- Progressive exertional dyspnea for 6 months
- Weight loss of 5 kg in 1 year

Medical history

- Never smoker
- Allergic rhinitis
- No regular medications
- Occupational and environmental exposure: an earphone repair worker with chronic exposure to welding fumes
- Unremarkable family history

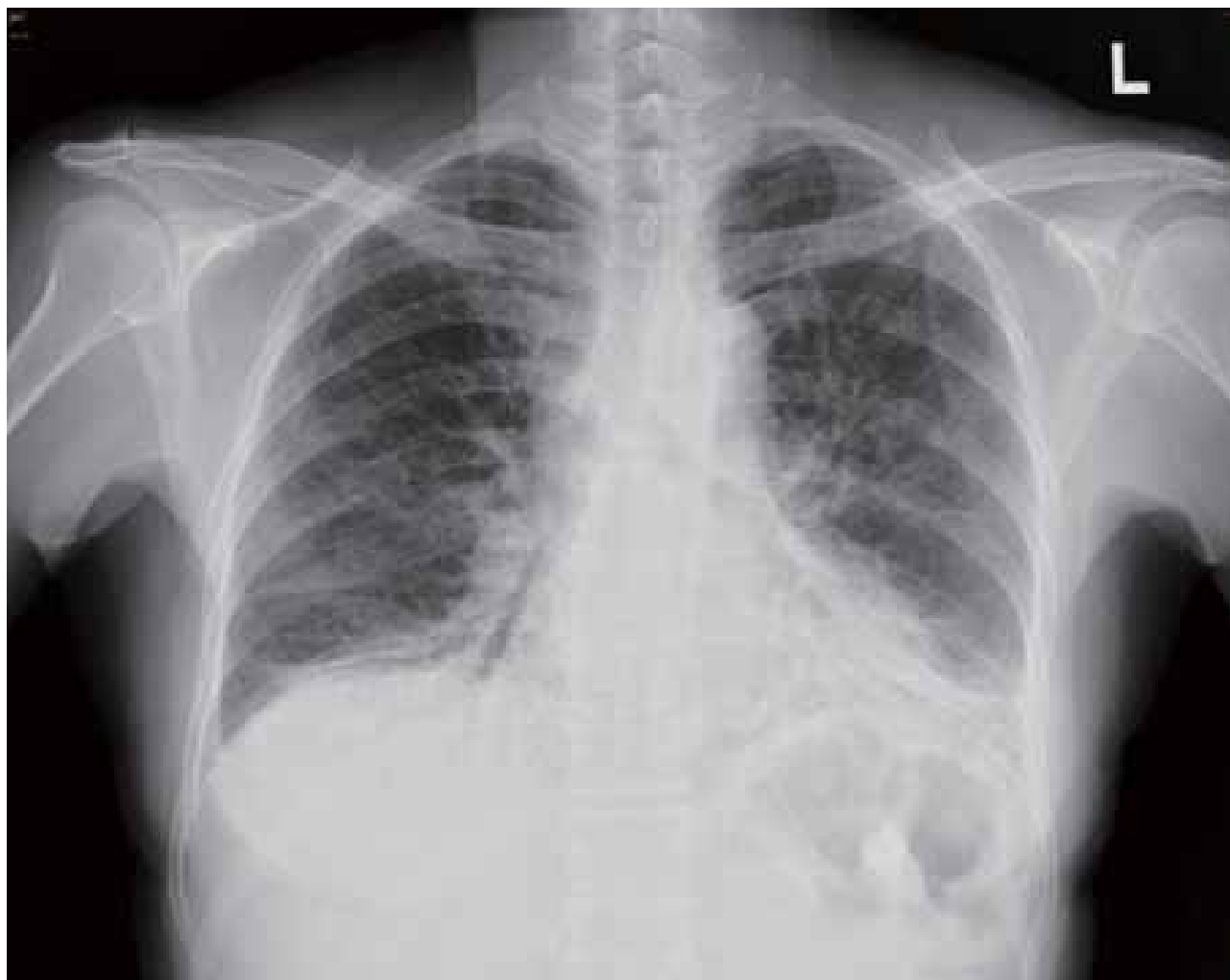Physical examination

- Heart rate: 98 bpm
- SpO₂: 97% on ambient air
- Lung auscultation: inspiratory fine crackles at the bilateral lung bases
- Nail clubbing
- No arthralgia

Laboratory findings

- Eosinophils: 2.7%
- Antinuclear antibody: 1:640
- Rheumatoid factor: 122 IU/mL
- Anti-Ro: > 240 EliAU/mL
- Anti-La: > 320 EliAU/mL
- SCL-70: < 0.4 EliAU/mL
- Jo-1: 0.4 EliAU/mL

Figure 1: Chest radiography findings



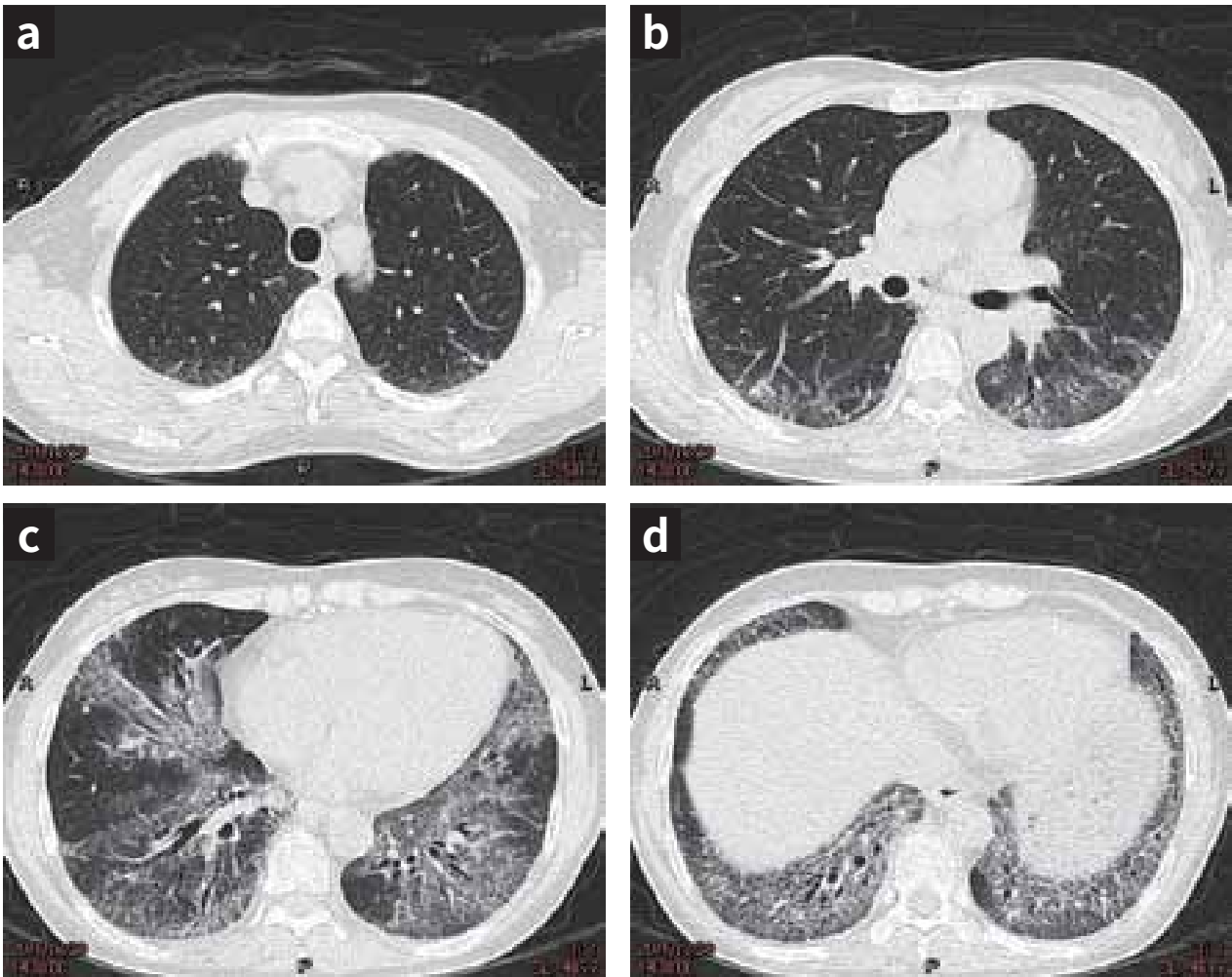
A chest radiograph shows basal-predominant consolidation and ground-glass opacities with reticulation.

Pulmonary function test findings

Parameter	Value
FVC	74.4% predicted
FEV ₁	83.9% predicted
FEV ₁ /FVC	92.9%
TLC	72.6% predicted
D _{LCO}	28.6% predicted

Conclusion: Mild restrictive ventilatory defect with severely reduced D_{LCO}

Figure 2a-2d: HRCT findings



HRCT shows bilateral basal-predominant ground glass opacities with reticulation and traction bronchiectasis, suggesting nonspecific interstitial pneumonia (NSIP).

Diagnosis

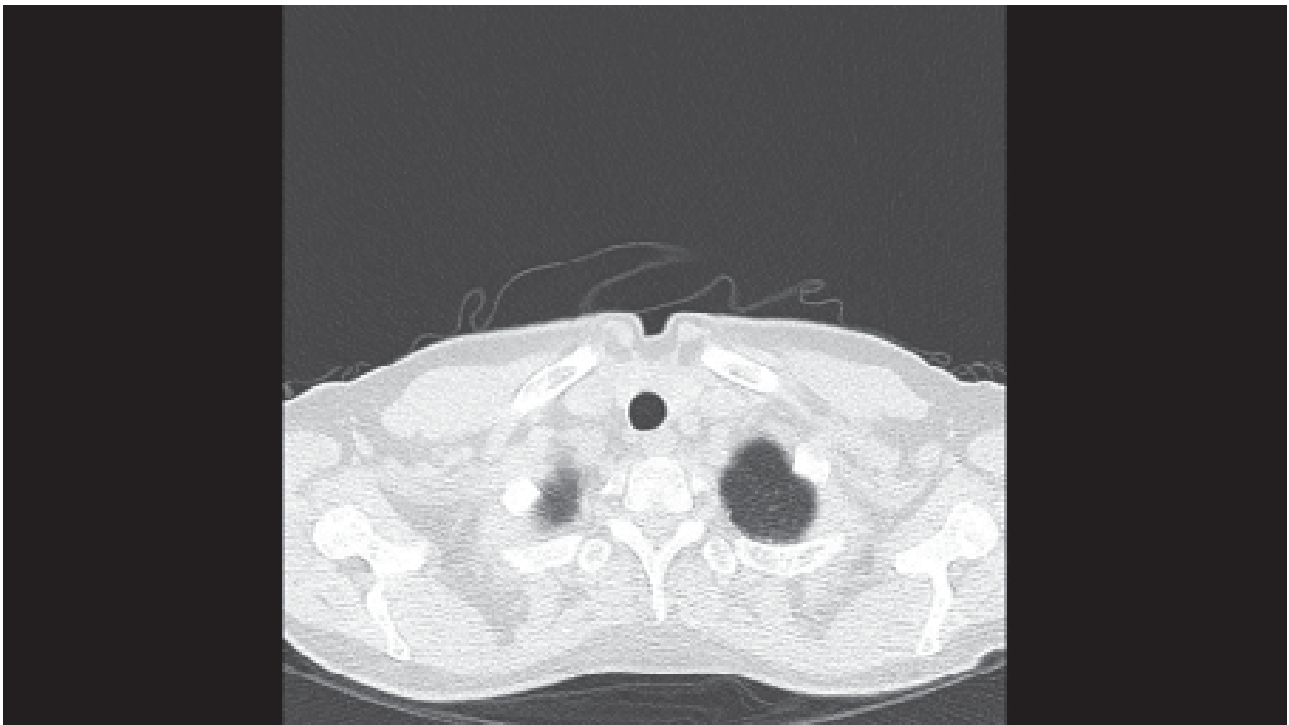
- HRCT findings suggested NSIP, and laboratory tests were positive for connective tissue disease. Therefore, the patient was diagnosed with CTD-ILD.
- A rheumatologist confirmed the diagnosis of Sjögren's syndrome.

Treatment and course

- The patient initially received prednisolone (30 mg/day), azathioprine (50 mg bid), and hydroxychloroquine (200 mg bid). Three months later, her chest X-ray showed partial resolution of the ground glass opacities. Her body weight increased from 40 to 44 kg. FVC remained unchanged, and D_{LCO} increased from 28.6% to 52.0%.
- After 2 years, she was in stable condition, although she required maintenance therapy with prednisolone (5-10 mg/day) and azathioprine (50 mg bid).

References

1. Ahuja J, Arora D, Kanne JP, Henry TS, Godwin JD. Imaging of pulmonary manifestations of connective tissue diseases. *Radiol Clin North Am* 2016;54(6):1015-1031.
2. Kreider M, Highland K. Pulmonary involvement in Sjögren syndrome. *Semin Respir Crit Care Med* 2014;35(2):255-264.



III. Treatment of IPF



Management of Idiopathic Pulmonary Fibrosis

Idiopathic pulmonary fibrosis (IPF) is a progressive lung disease characterized by progressive deterioration of the pulmonary function and episodes of acute exacerbation. In the past, patients with IPF usually exhibited poor outcomes because of the lack of effective treatments. In recent years, the introduction of new antifibrotic agents (nintedanib and pirfenidone) has facilitated better management of IPF. Clinical trials have confirmed that these new antifibrotic agents decrease physiological progression, prevent exacerbation, and improve the quality of life. Of note, these agents may cause significant adverse effects that, if not appropriately managed, can lead to long-term discontinuation of antifibrotic treatment.

The 2015 International IPF Therapy Guidelines, which were published by the ATS/ERS/JRS/ALAT, made recommendations for and against specific pharmacotherapies (Table). Non pharmacotherapies, including pulmonary rehabilitation, lung transplantation, and oxygen therapy, are also important for IPF and help in improving the quality of life of patients.

Recommendations by the 2011 and 2015 ATS/ERS/JRS/ALAT guidelines

Conditional recommendations for use

- Pirfenidone [2015]
- Nintedanib [2015]
- Antiacid therapy [2015]
- Pulmonary rehabilitation [2011]
- Corticosteroids for acute exacerbation [2011]
- Lung transplantation [2011]
- Long-term oxygen therapy for IPF with resting hypoxemia [2011]

Conditional recommendation against use

- Dual endothelin receptor antagonists (macitentan and bosentan) [2015]
- Phosphodiesterase 5 inhibitor (sildenafil) [2015]
- N-acetylcysteine monotherapy [2015]
- Mechanical ventilation for respiratory failure caused by IPF [2011]

Strong recommendation against use

- Anti-coagulation (warfarin) [2015]
- Combination of prednisone, azathioprine, and N acetylcysteine [2015]
- Selective endothelin receptor antagonist (ambrisentan) [2015]
- Imatinib [2015]
- Interferon- γ 1b [2011]
- Corticosteroid monotherapy or combined immunomodulator [2011]



IPF treated with nintedanib

**IPF treatment with OFEV®:
Stability with good compliance
and no side effects**

Dr. Chi-Wei Tao

Division of Respiratory Therapy,
Department of Internal Medicine,
Cheng-Hsin General Hospital,
Taipei, Taiwan

Clinical pearls

- IPF is a fatal disease because of the progressive loss of lung function. In the past decades, we had little to offer patients diagnosed with IPF.
- Nintedanib, a multiple tyrosine kinase inhibitor, can reduce the decline in FVC and the acute exacerbation rate without causing severe adverse effects. Thus, nintedanib is a novel therapeutic option for IPF patients.

Patient profile

Case presentation

- 65-year-old woman
- A housewife
- Dry cough with exertional dyspnea for several months

Medical history

- History of old pulmonary tuberculosis, chronic bronchitis, allergic rhinitis, and gastroesophageal reflux
- The patient sought evaluation at our clinic and used medications, including budesonide nasal spray and Foster (beclomethasone and formoterol) inhaler. She was lost to follow-up for 2 years.
- No cigarette smoking or alcohol consumption
- No pets
- Unremarkable family, exposure, and drug histories

Physical examination

- Height, 155 cm; weight, 52 kg
- SpO₂: 97% on ambient air
- Bibasilar crackles on lung auscultation
- Nail clubbing
- No arthralgias, no skin rashes

Laboratory findings

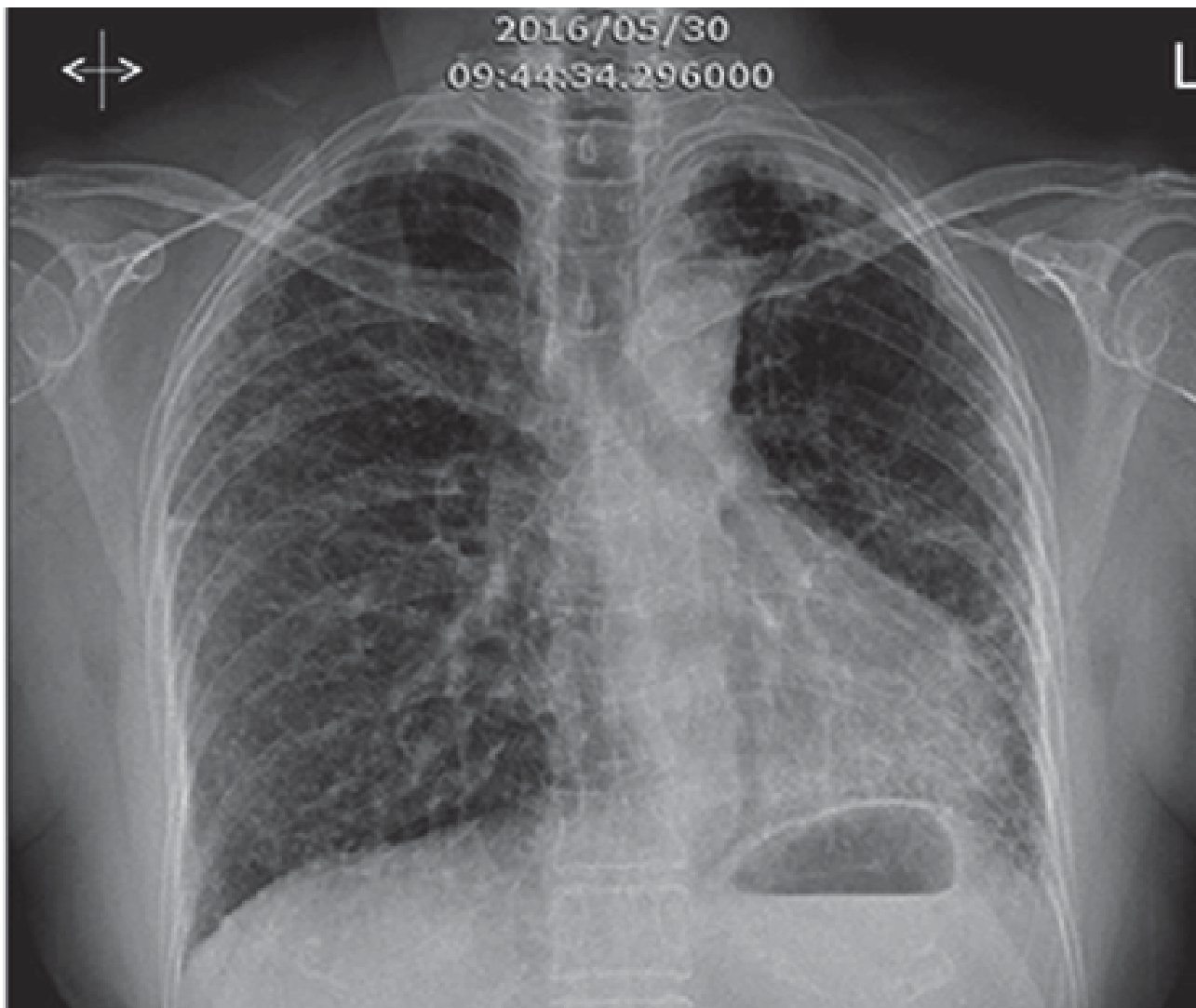
- Normal CBC and biochemistry results
- RF, ANA, anti-SSA/SSB, anti-Jo-1, anti-Scl-70 negativity
- Negative acid-fast staining in three sets of sputum samples

Pulmonary function test findings

Parameter	Value
FVC (liter)	1.46
FVC	58% predicted
FEV ₁ (liter)	1.22
FEV ₁	62% predicted
FEV ₁ / FVC	83%
TLC	53% predicted
RV	46% predicted
IC	51% predicted
VC	58% predicted
D _{LCO}	41% predicted
D _{LCO} / VA	90% predicted

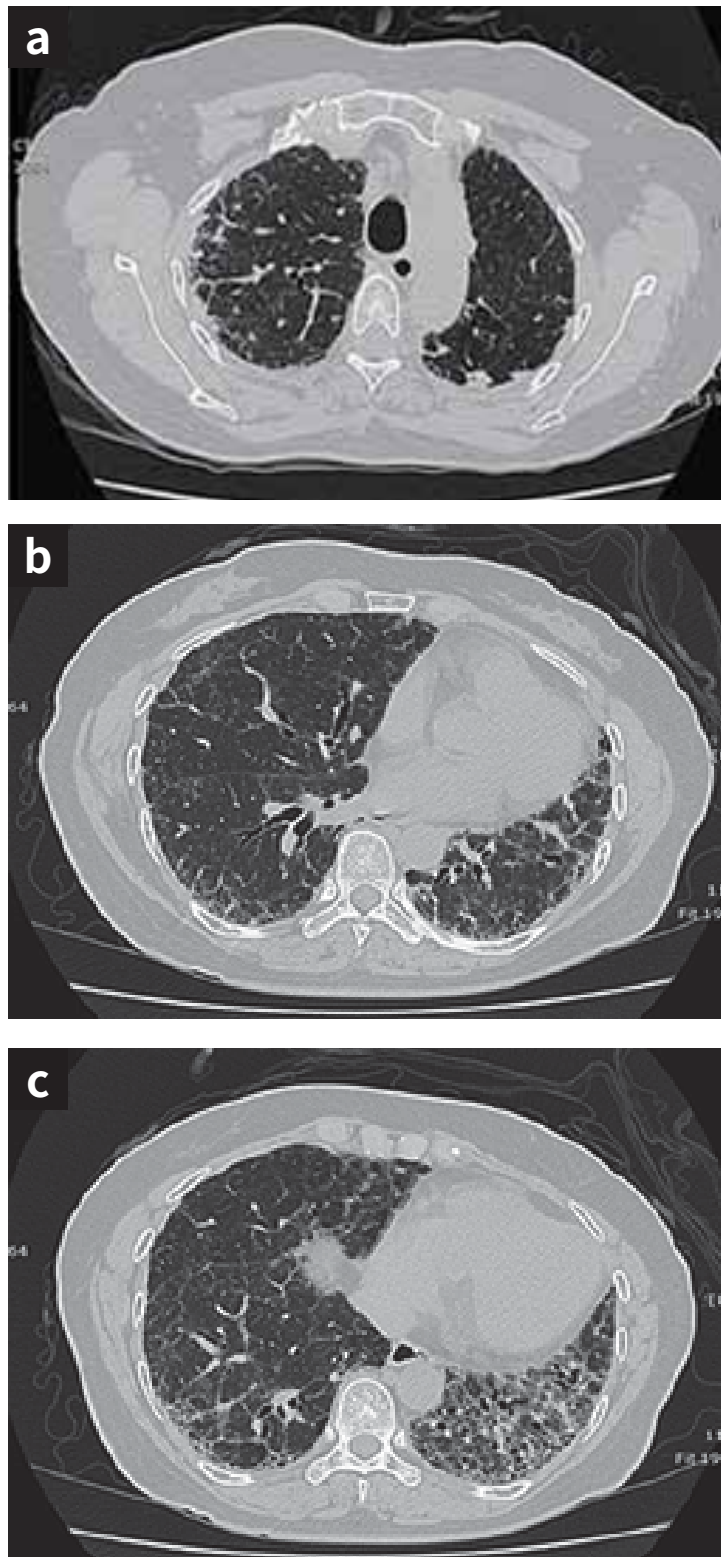
Conclusion: Moderate restrictive ventilatory impairment and moderate reduction in the diffusion capacity

Figure 1: Chest radiography findings: 2016/5/30



Reticular infiltration can be seen over the bilateral peripheral lung fields.

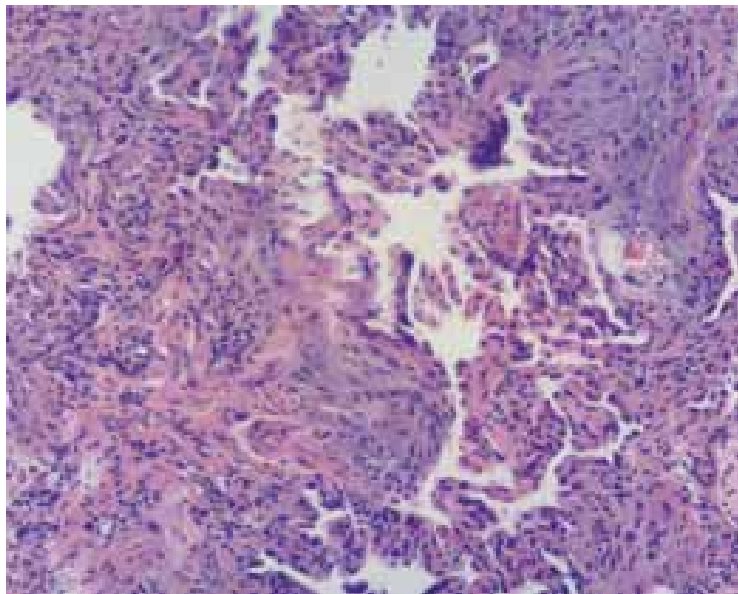
Figure 2a-2c: HRCT findings (2016/6/6)



There is subpleural, basal predominance, with asymmetrical distribution and ground glass opacities over the lower left lobe with peribronchovascular bundle thickening. A reticular pattern and honeycombing without traction bronchiectasis can be seen.

Figure 3: Histopathological analysis (2016/6/20) of surgical specimens (diagnostic VATS and RUL and RLL wedge resections)

Massive dilatation of air spaces with disturbed organization and surrounding inflammatory fibrotic tissue. The cystic dilatation is lined by a metaplastic cuboidal-to-bronchiolar type of epithelium. Nearly all alveolar parenchyma adjacent to the dilatation shows moderate-to-severe interstitial fibrosis. There is no evidence of granulomatous inflammation.



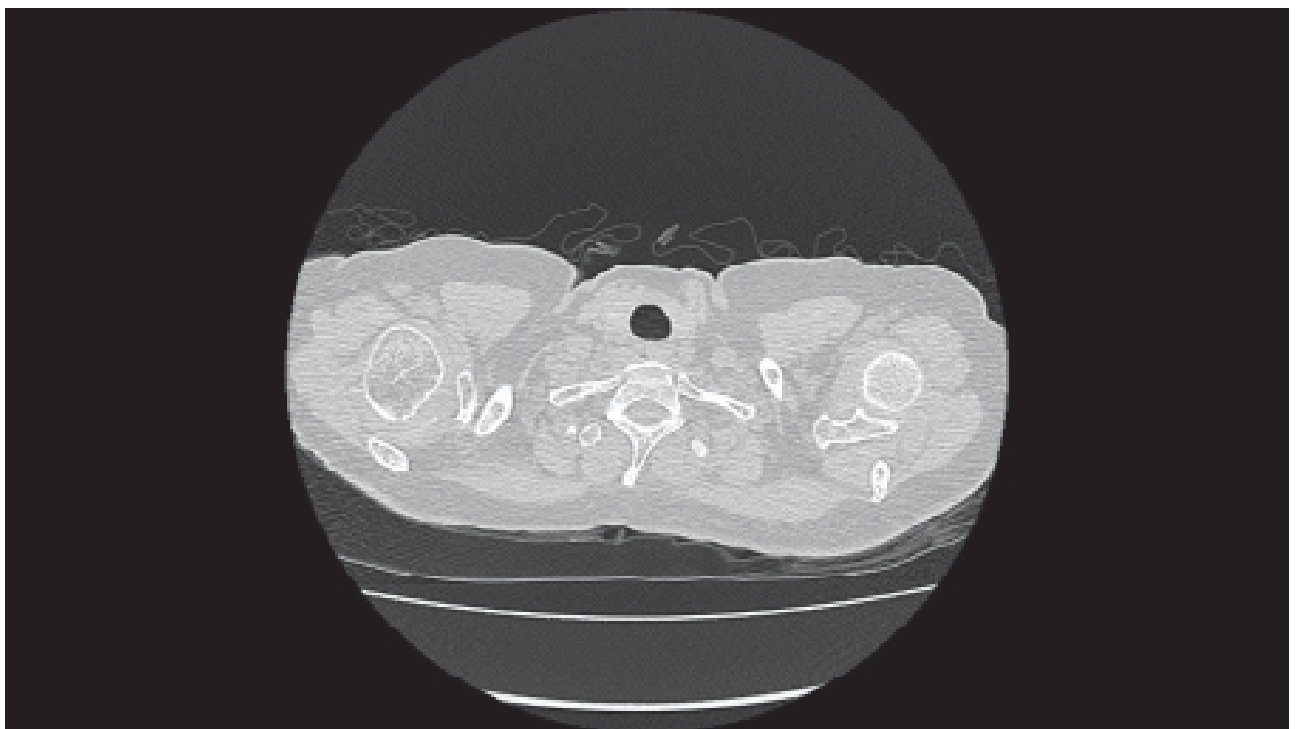
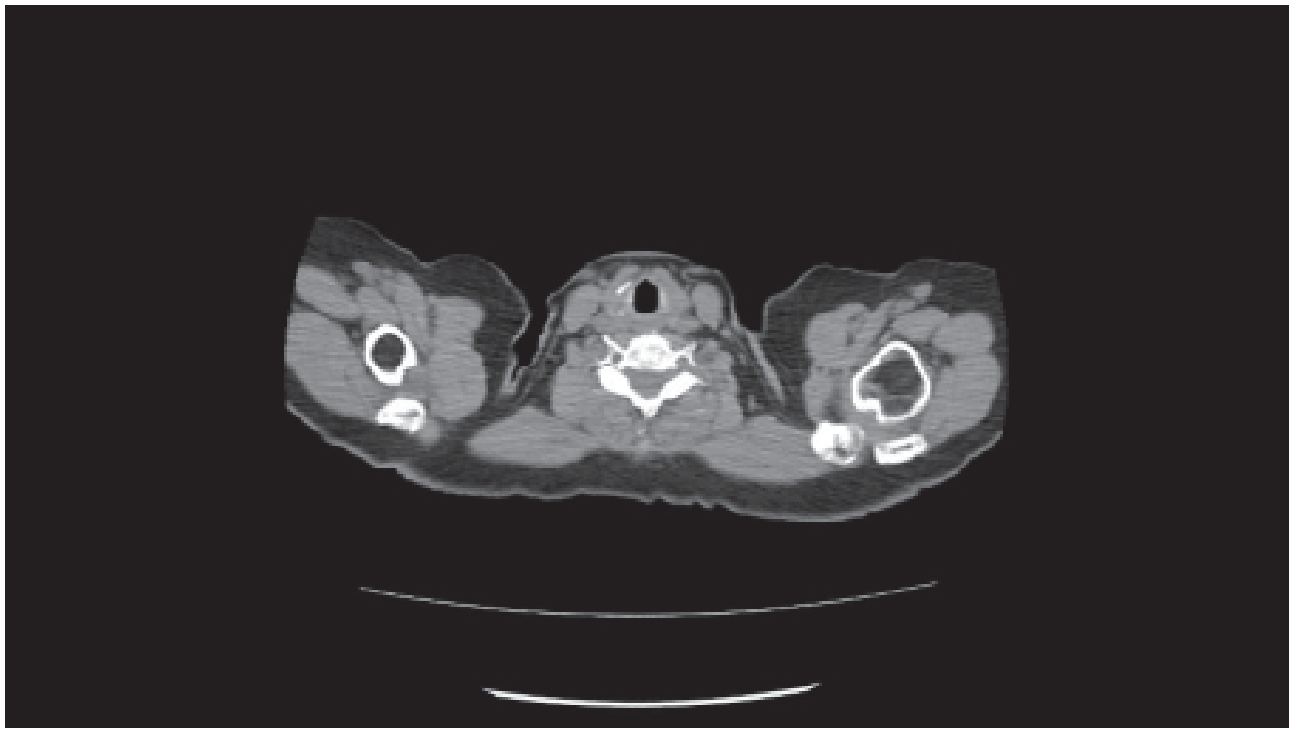
Histopathological analysis reveals unusual interstitial pneumonitis..

Nintedanib treatment

- Following histopathological confirmation of the diagnosis, nintedanib treatment (Ofev®; 150 mg twice daily) was initiated on 2017/7/5.
- Her lung function remained stable after Ofev® treatment FVC of 61% and a D_{LCO} of 33% on 2017/8/30
- The symptoms, including dry cough and exertional Her condition was relatively stable, with no obvious an anti-fibrotic agent.

References

1. Richeldi L, Costabel U, Selman M, Kim DS, Hansell DM, Nicholson AG, et al. Efficacy of a tyrosine kinase inhibitor in idiopathic pulmonary fibrosis. *N Engl J Med* 2011;365(12):1079-87.
2. Richeldi L, du Bois RM, Raghu G, Azuma A, Brown KK, Costabel U, et al. Efficacy and safety of nintedanib in idiopathic pulmonary fibrosis. *N Engl J Med* 2014;370(22):2071-82.





Nintedanib treatment for IPF: management of side effects.

Management of adverse effects
caused by nintedanib treatment
in patients with idiopathic
pulmonary fibrosis

Dr. Hsin-Kuo Ko

Department of Chest Medicine,
Taipei Veterans General Hospital,
Taipei, Taiwan

Clinical pearls

- In patients with idiopathic pulmonary fibrosis (IPF), nintedanib prevents a decline in FVC, which slows down disease progression. However, nintedanib is frequently associated with adverse effects, including diarrhea (62%), nausea (24%), abdominal pain (15%), liver function impairment (14%), vomiting (12%), poor appetite (11%), body weight loss (10%), headache (8%), and hypertension (5%)^{1,2}.
- Close monitoring for and effective management of nintedanib-related adverse effects can prevent the immediately life-threatening serious adverse effects that results in the long-term discontinuation of nintedanib in IPF patients.

Patient profile

Case presentation

- 86-year-old man
- A retired teacher living in northern Taiwan
- Intractable dry cough and progressive dyspnea on exertion during for the last 6 months

Medical history

- History of aortic aneurysm and under regular follow-up at the Cardiovascular Surgery Clinic
- Smoked 1 one pack per day for 40 years and quit 10 years ago
- No alcohol, consumption or drug use
- No pets
- Unremarkable family, exposure, and drug histories

Physical examination

- Heart rate: 106 bpm; weight ,66 kg, BMI, 23 kg/m²
- SpO₂: 92% on ambient air
- Bibasilar crackles on lung auscultation
- Nail clubbing
- No lower extremity edema
- No arthralgias, no skin rashes

Laboratory findings

- Normal CBC and biochemistry results
- RF, ANA, SSA/SSB, Jo-1 and Scl-70 negativity; normal CK levels

Pulmonary function test findings

Parameter	Value
FVC (liter)	2.90
FVC	70% predicted
FEV ₁ (liter)	1.90
FEV ₁	98% predicted
FEV ₁ /FVC	91%
TLC	75% predicted
RV	83% predicted
IC	73% predicted
VC	70% predicted
D _{LCO}	23% predicted
D _{LCO} / VA	30% predicted

Conclusion: Mild restrictive ventilatory impairment and severe impairment in the diffusion capacity

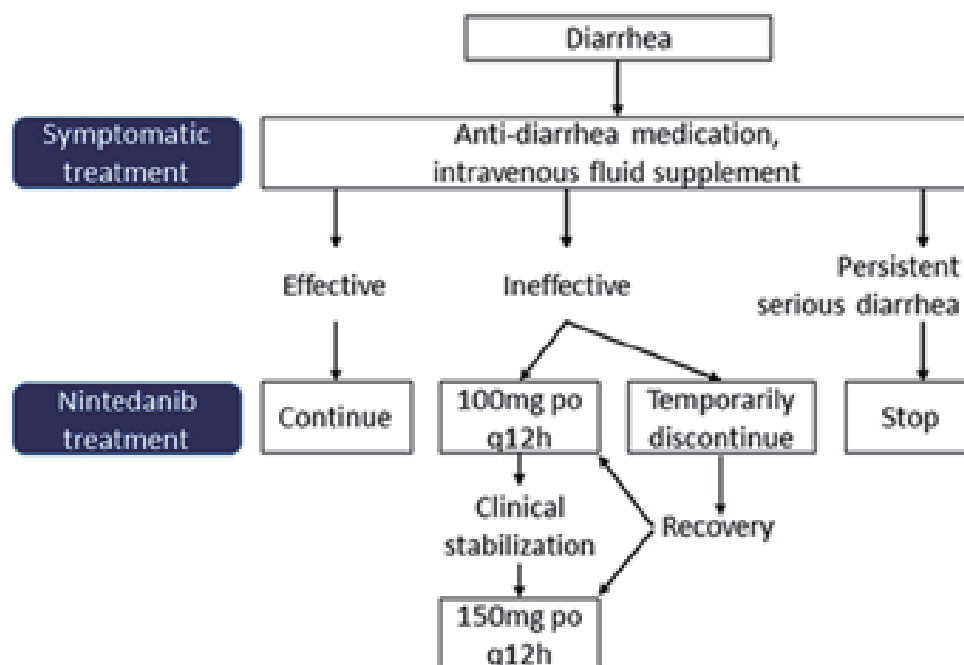
HRCT findings(2017/2/16) (definite UIP pattern)

- Subpleural and basal predominance
- Reticular pattern
- Honeycombing without traction bronchiectasis
- No findings inconsistent with a UIP pattern

Treatment of IPF and management of treatment-related adverse effects

The patient presented with a UIP pattern on HRCT and restrictive ventilatory impairment in a pulmonary function test. Markers of autoimmune diseases were absent. Therefore, a diagnosis of IPF was made. Oral nintedanib (Ofev®; 150 mg twice daily) was initiated on March 27, 2017. Three days after the initiation of nintedanib treatment, the patient developed diarrhea with a frequency of 3 times per day (grade 1); there was no evidence of dehydration. The diarrhea resolved after the oral administration of loperamide (2 mg three times a day). Nintedanib treatment was continued at the same dose (Figure 1)³.

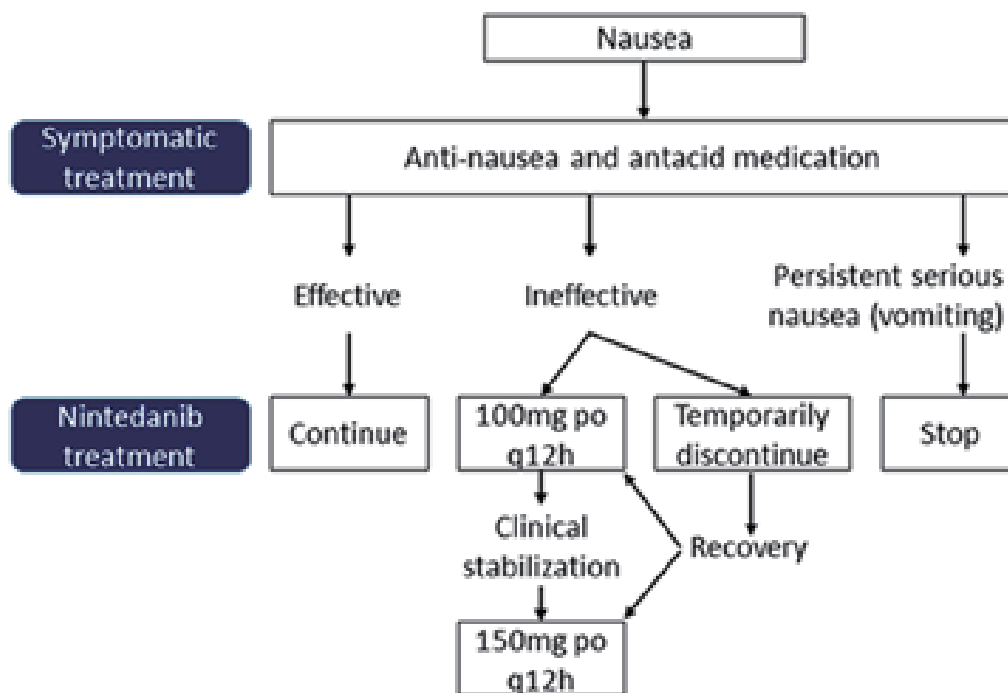
Figure 1



Flowchart for the management of diarrhea as a side effect of nintedanib treatment. Diarrhea was defined as an increased frequency of stool passage and soft stools.

One week after the initiation of nintedanib treatment, the patient complained of nausea and poor appetite that did not cause dehydration and weight loss (grade 2). Oral mosapride (5 mg three times a day) and prochlorperazine (5 mg three times a day) were prescribed for 3 days, but the symptoms were persistent and he developed dehydration. Intravenous fluid supplements were given. The dose of nintedanib was reduced to 100 mg twice a day for 1 week and subsequently titrated to 150 mg twice a day (Figure 2)³.

Figure 2

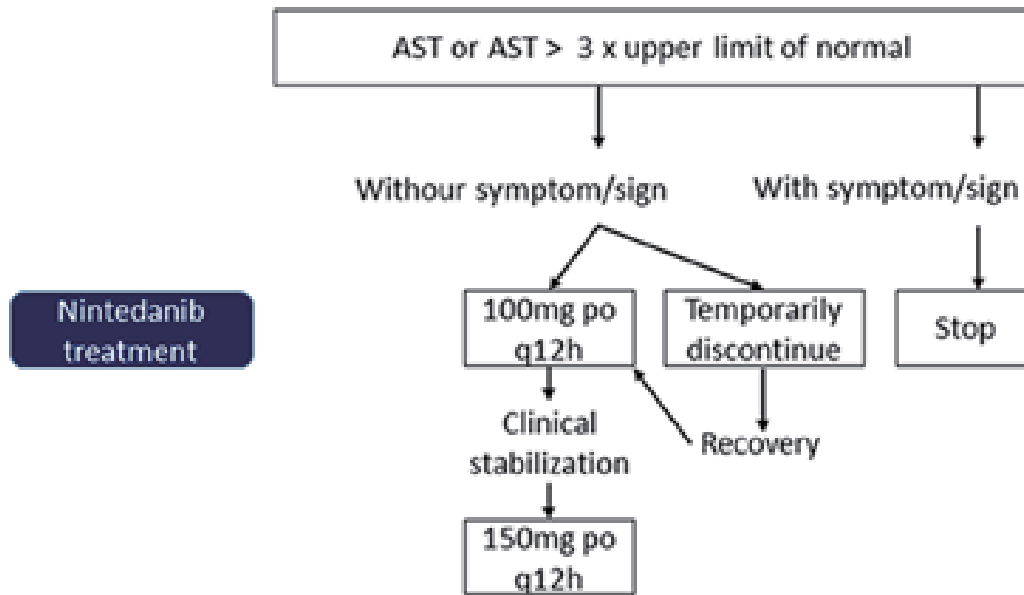


Flowchart for the management of nausea as a side effect of nintedanib treatment. Nausea (vomiting) was defined as general weakness, anorexia, loss of appetite, and weight loss.

One month after the initiation of nintedanib treatment, a routine follow-up liver function test revealed elevated ALT/AST [132/145 U/L (grade 2)] levels without liver function impairment–related symptoms.

Nintedanib was discontinued for 2 weeks. The ALT/AST levels returned to normal, and nintedanib (100 mg twice a day) was initiated again (Figure 3)³. A liver function test was performed every month.

Figure 3



Flowchart for the management of impaired liver function as a side effect of nintedanib treatment. The signs/symptoms of impaired liver function included general weakness, fatigue, persistent mild fever, tea-colored urine, icteric sclera and skin, loss of appetite, nausea, vomiting, skin rashes, and systemic itching.

References

1. Richeldi L, Costabel U, Selman M, Kim DS, Hansell DM, Nicholson AG, et al. Efficacy of a tyrosine kinase inhibitor in idiopathic pulmonary fibrosis. *N Engl J Med* 2011;365(12):1079-87.
2. Richeldi L, du Bois RM, Raghu G, Azuma A, Brown KK, Costabel U, et al. Efficacy and safety of nintedanib in idiopathic pulmonary fibrosis. *N Engl J Med* 2014;370(22):2071-82.
3. Package insert of Ofev Soft Capsules 150 mg, assessed at www.fda.gov.tw.



Lung transplantation for IPF

Lung transplantation in a patient with idiopathic pulmonary fibrosis

Dr. Chung-Shu Lee, Dr. Kuo-Chin Kao

Department of Thoracic Medicine,
Chang Gung Memorial Hospital,
Taoyuan, Taiwan

Clinical pearls

- Idiopathic pulmonary fibrosis (IPF) is characterized by exertional dyspnea and progressive deterioration of the lung function. IPF has a great impact on the quality of life. There is no complete cure for the condition, even with optimal treatment.
- IPF is one of the most common diffuse parenchymal lung diseases among referrals for lung transplantation and the second most common disease for which lung transplantation is performed^[1,2].
- IPF patients exhibit the highest mortality rate among the patients on lung transplantation waiting lists^[3]. Therefore, early referral for lung transplant evaluation should be considered^[4].
- Reasons for referral for lung transplantation include radiographic and/or histological evidence of usual interstitial pneumonia (UIP) and any of the following^[5]:
 - A diffusion capacity (D_{LCO}) of < 40% predicted
 - A forced vital capacity (FVC) of < 80% predicted
 - Any dyspnea or functional limitation attributable to lung disease
 - An oxygen saturation of <89%, even if it is only during exertion
- Indications for inclusion in a lung transplantation waiting list include the following^[5]:
 - A decline in FVC of $\geq 10\%$ during 6 months of follow-up (a decline of $\geq 5\%$ may also warrant listing)
 - A decline in D_{LCO} of $\geq 15\%$ during 6 months of follow-up
 - In the 6-minute walk test: An oxygen desaturation of <88% or a walking distance of <250 meters or a decline of >50 meters in the distance walked over 6 months
 - Pulmonary hypertension on right heart catheterization or transthoracic echocardiography
 - Hospitalization because of respiratory depression, pneumothorax, or acute exacerbation

Patient profile

Case presentation

- 63-year-old man
- A worker who lived in northern Taiwan
- IPF was diagnosed in January 2016
- Intermittent, progressive dyspnea for 2 years and acute worsening in over the past 2 months
- After treatment for > 1 year, he underwent bilateral lung transplantation on 2017/06/19 because of progressive symptoms with an acute exacerbation episode.

Medical history

- Diabetes mellitus treated with oral hypoglycemic agents
- No smoking, no alcohol consumption
- Unremarkable family history

Physical examination

- Heart rate: 98 bpm
- SpO₂: 93% on ambient air
- Bibasilar crackles on lung auscultation
- Nail clubbing
- Bilateral lower extremity edema

Laboratory findings

- Normal CBC and biochemistry results
- RF, ANA, anti-ENA, and anti-CENP negativity; normal C3 and C4 levels
- Cardiac echo: Moderate pulmonary hypertension (maximum gradient: 62 mmHg), mild tricuspid regurgitation, dilated right atrium and ventricle, hypertrophy of the right ventricle, mild pericardial effusion

Pulmonary function test finding (serial follow-up findings)

Date	FVC (L)	FVC (% predicted)	FEV ₁ (L)	FEV ₁ (% predicted)	D _{LCO} (% predicted)
2016.04	2.36	61	2.01	65	27
2016.09	2.17	60	1.98	68	-
2017.04	2.22	60	1.95	65	20

Conclusion: Mild decrease in FVC and severe decline in of D_{LCO} (from 27% to 20%)

Bilateral lung transplantation on 2017.06.19					
2017.07	1.87	51	1.60	55	-
2017.09	1.60	44	1.45	50	-

Figure 1: Chest radiography findings (2016/2/19)

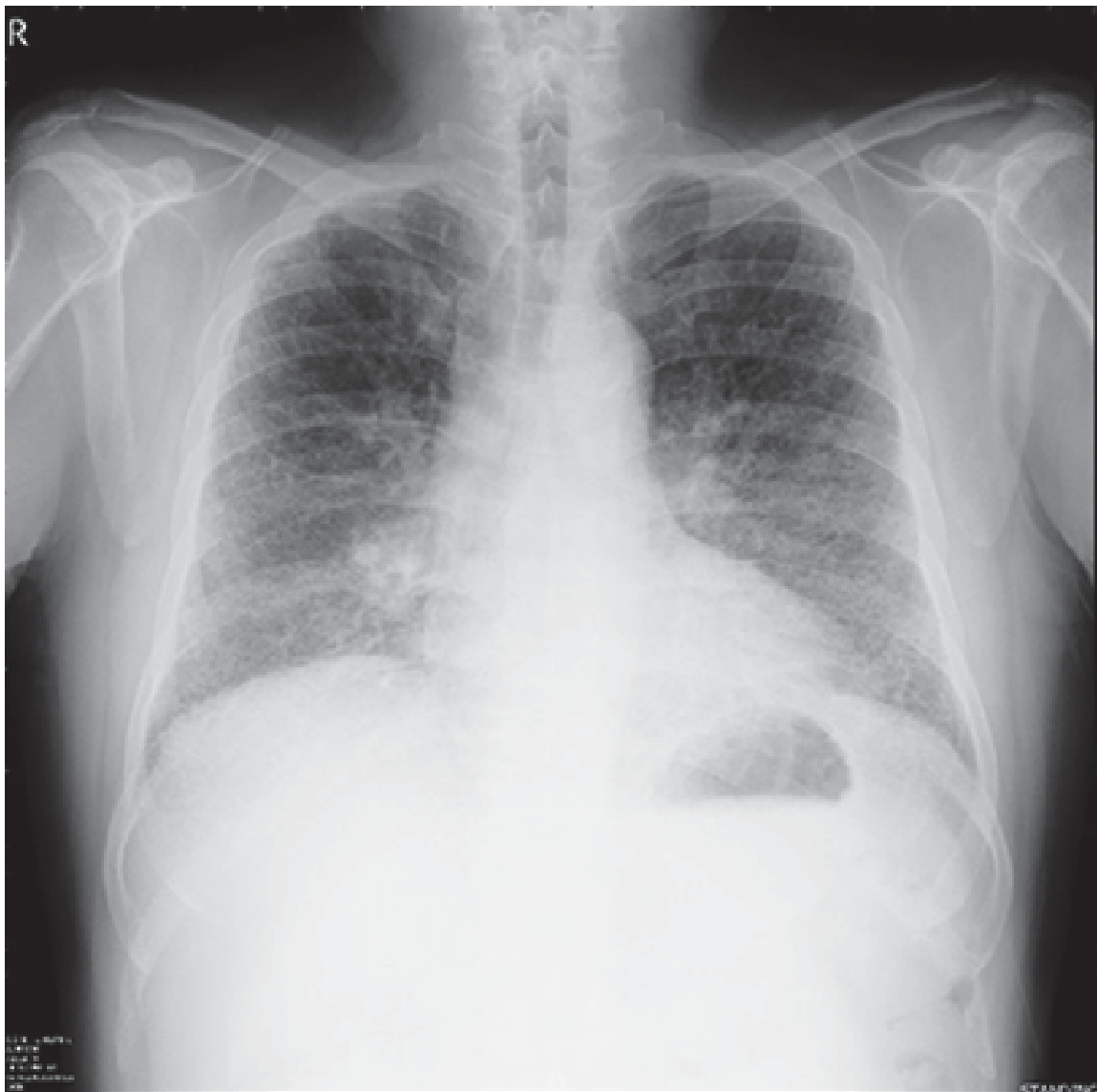
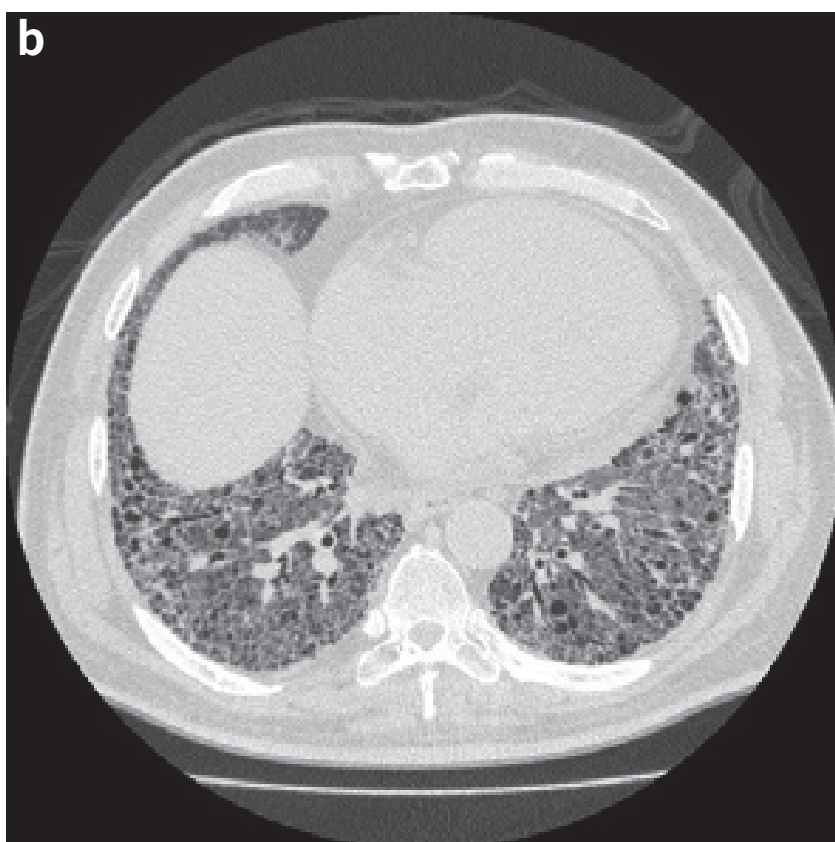
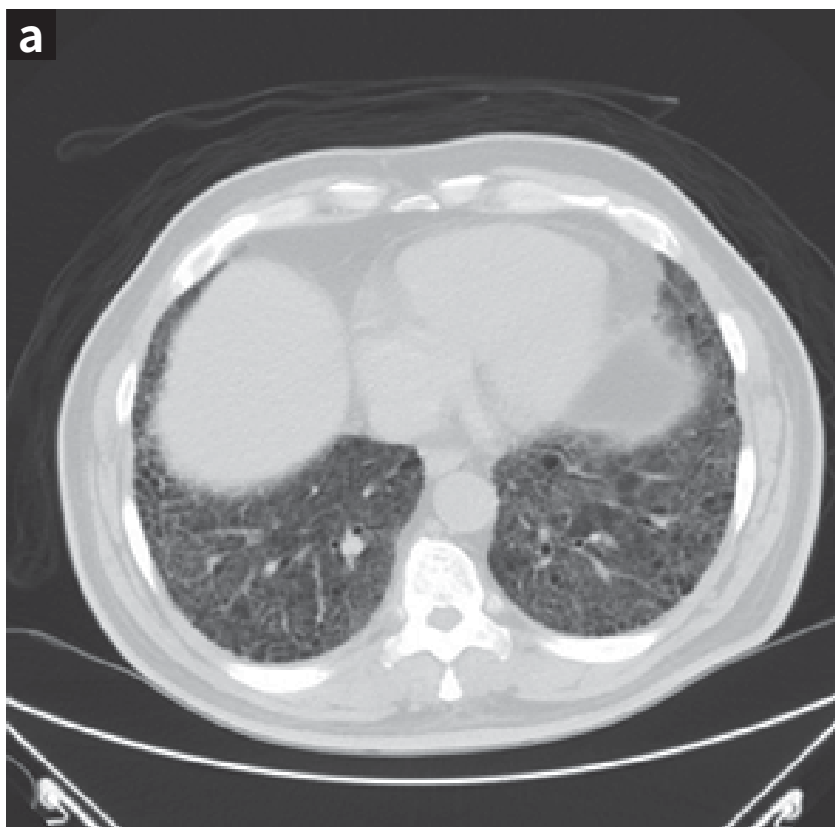
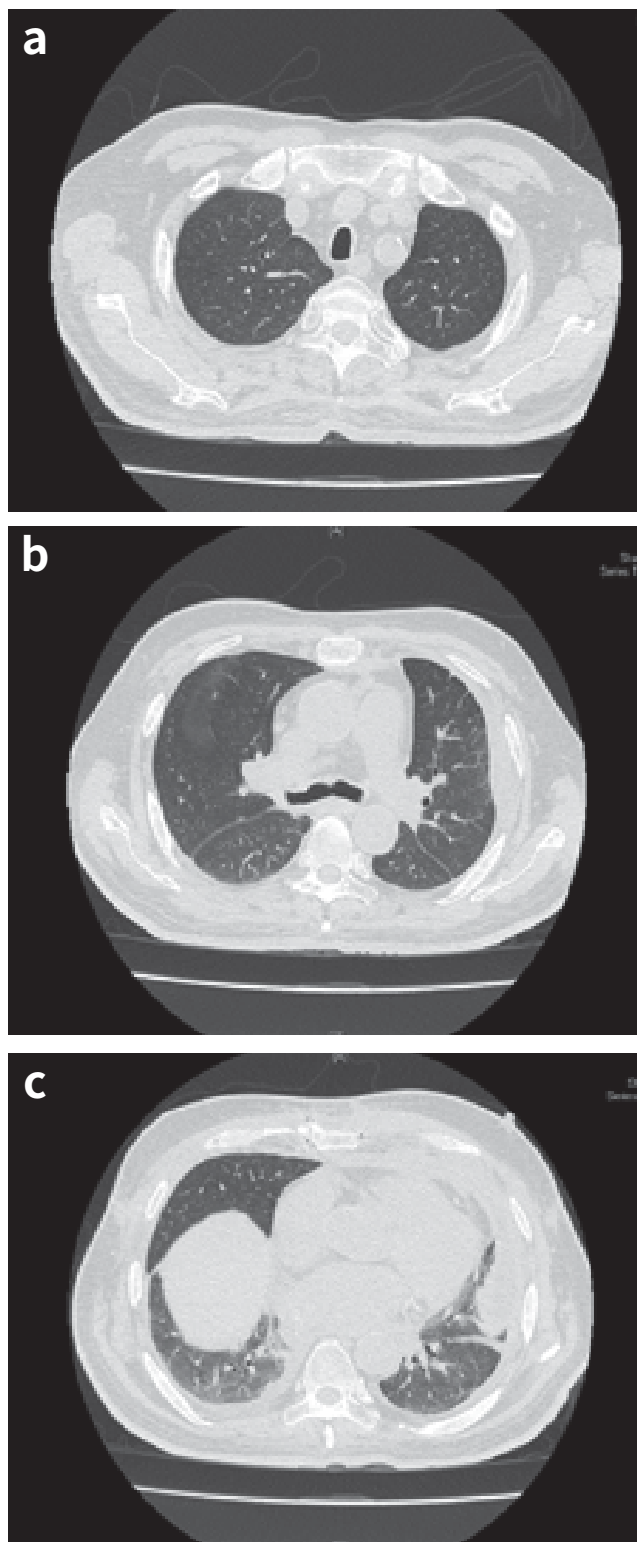


Figure 2a (2016/01/28) and 2b(2017/04/11): HRCT findings



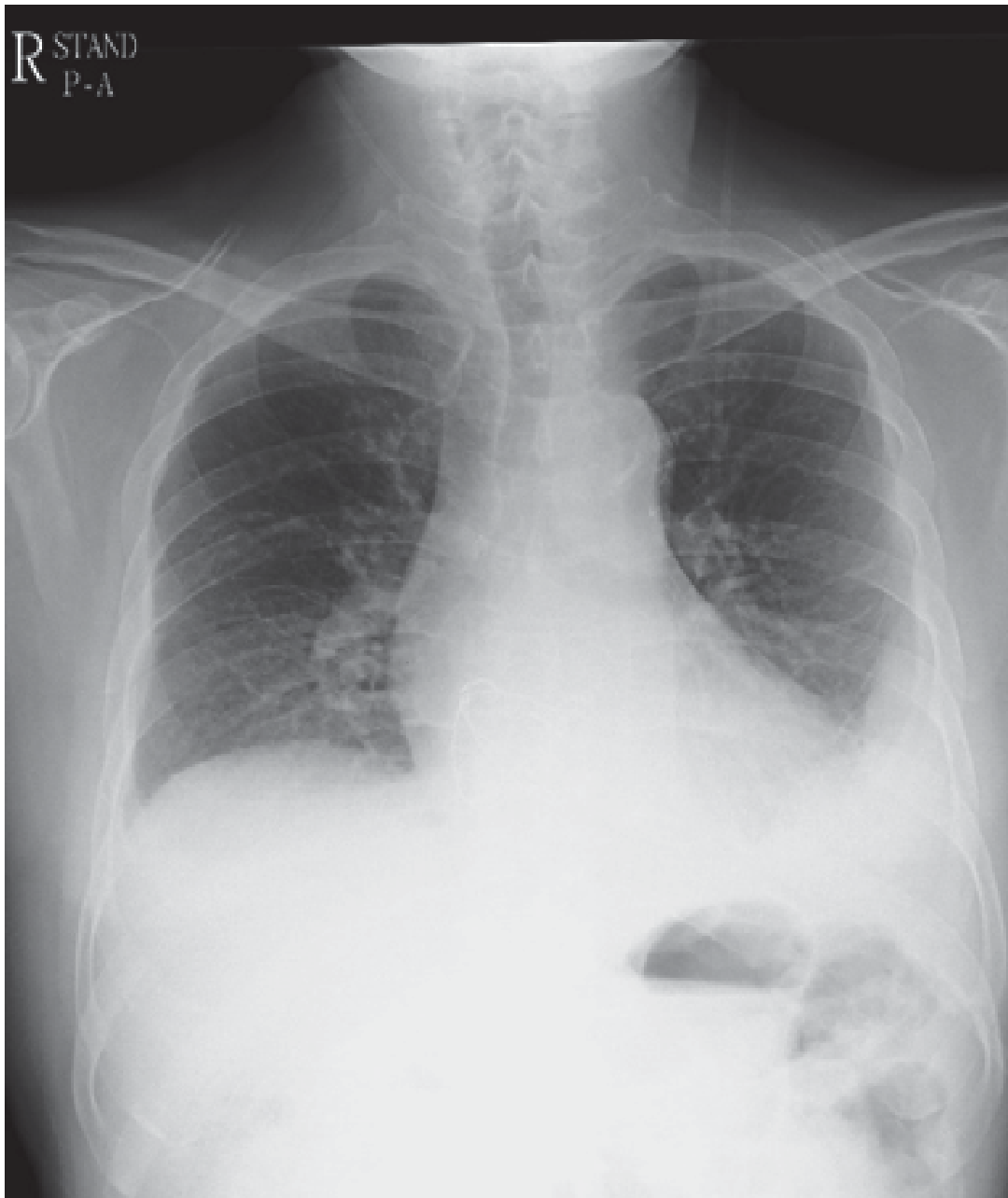Progressive pulmonary fibrosis and honeycombing can be seen.

Figure 3a-3c:HRCT after lung transplantation (2017/10/13)



S/P bilateral lung transplantation. Bilateral pleural effusion, encapsulated on the left with slight regression, with left pleural thickening that pleuritis should be considered. Partial collapse of LLL lung.

Figure 4: Chest radiograph obtained 3 months after bilateral lung transplantation (2017/10/02)



After bilateral lung transplantation on 2017/6/9, the patient received continuous pulmonary rehabilitation to improve his pulmonary function.

References

1. Alalawi R, Whelan T, Bajwa RS, Hodges TN. Lung transplantation and interstitial lung disease. *Curr Opin Pulm Med* 2005;11(5):461-6.
2. Yusen RD, Edwards LB, Kucheryavaya AY, Benden C, Dipchand AI, Goldfarb SB, et al. The Registry of the International Society for Heart and Lung Transplantation: Thirty-second Official Adult Lung and Heart-Lung Transplantation Report--2015; Focus Theme: Early Graft Failure. *J Heart Lung Transplant* 2015;34(10):1264-77.
3. Thabut G, Mal H, Castier Y, Groussard O, Brugière O, Marrash-Chahla R, et al. Survival benefit of lung transplantation for patients with idiopathic pulmonary fibrosis. *J Thorac Cardiovasc Surg* 2003;126(2):469-75.
4. Steinman TI, Becker BN, Frost AE, Olthoff KM, Smart FW, Suki WN, et al. Guidelines for the referral and management of patients eligible for solid organ transplantation. *Transplantation* 2001;71(9):1189-204.
5. Weill D, Benden C, Corris PA, Dark JH, Davis RD, Keshavjee S, et al. A consensus document for the selection of lung transplant candidates: 2014--an update from the Pulmonary Transplantation Council of the International Society for Heart and Lung Transplantation. *J Heart Lung Transplant* 2015;34(1):1-15.

IV. IPF Clinical Course



Idiopathic pulmonary fibrosis clinical course: Acute exacerbation, nonpharmacologic therapies and palliative care issues in end-of-life care

Acute exacerbations of idiopathic pulmonary fibrosis (AE-IPF) is unpredictable and associated with a very high short-term mortality rate (>50%) and a low mean survival periods (between 3 to 13 days). AE-IPF is essentially diagnosed by the appearance of newly developed ground glass opacities or airspace consolidation on HRCT images.

Physicians should distinguish between AE-IPF and other possible conditions that contribute to new HRCT findings, including heart failure, drug toxicity, bilateral pneumonia, and pulmonary embolism. Treatment regimens for AE-IPF include the use of broad-spectrum antibiotics and high doses of corticosteroids with or without immunosuppressive agents, despite limited evidence of the effectiveness of these therapies. Anti-fibrotic agents not only slow down the progression of IPF but also show promise in reducing preventing AE-IPF.

IPF is a progressive and ultimately fatal lung disease characterized by dyspnea, cough, and impaired quality of life. The optimal management strategy for IPF should include pharmacological and nonpharmacological treatment. The latter should address the patient's comorbidities, symptoms of breathlessness and fatigue, pulmonary rehabilitation, and end-of-life palliative care. Long-term oxygen therapy is recommended for patients who present with significant resting hypoxemia (strong recommendation, very low-quality evidence). With regard to IPF patients with respiratory failure, international guidelines suggest that most of these patients should not receive mechanical ventilation (weak recommendation low-quality evidence). Pulmonary rehabilitation is only weakly recommended for the majority of patients with IPF because of the lack of long-term follow-up studies; however, a growing body of evidence now demonstrates the short-term benefits of pulmonary rehabilitation in terms of the exercise capacity, dyspnea, the quality of life, and patients satisfaction.



IPF with AE

**Acute exacerbation of
idiopathic pulmonary fibrosis:
An eventually ominous
outcome?**

**Dr. Wann-Cherng Perng, Dr. Shih-En Tang,
Dr. Chih-Feng Chian, Dr. Chung-Kan Peng**

Division of Pulmonary and Critical Care Medicine,
Department of Medicine, Tri-Service General Hospital,
National Defense Medical Center, Taipei, Taiwan, R.O.C.

Clinical pearls

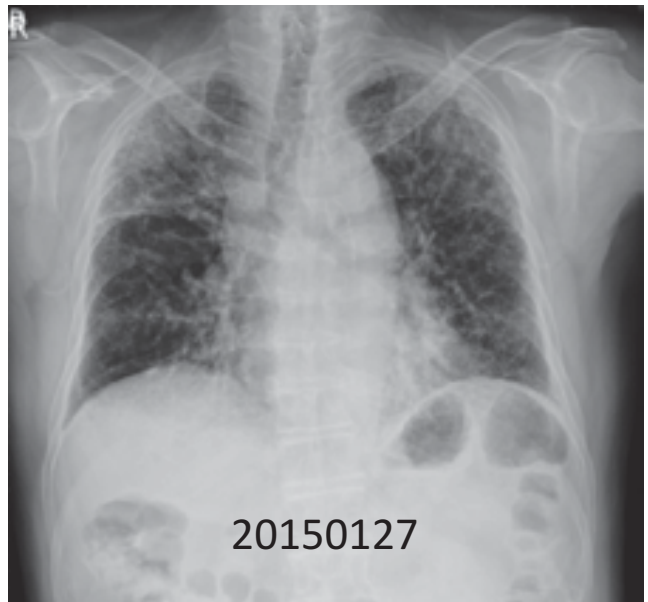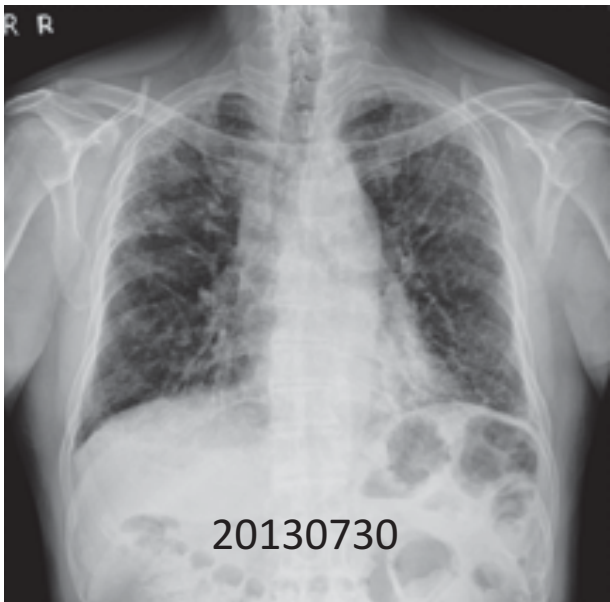
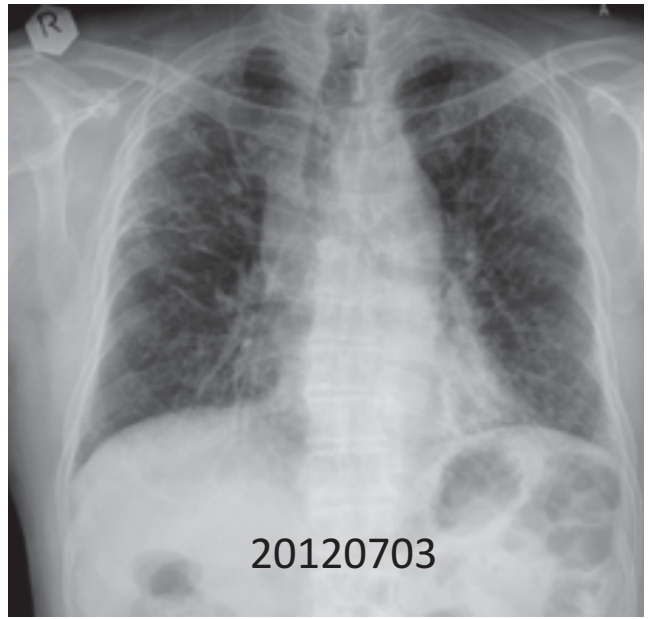
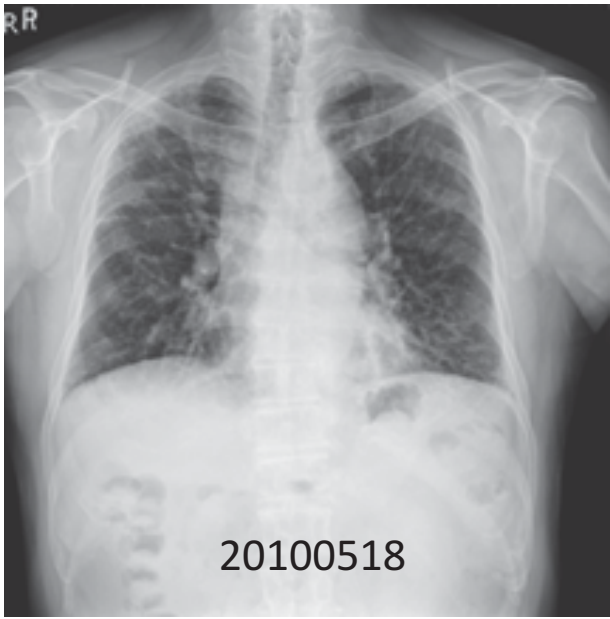- AE-IPF is unpredictable and associated with a short-term mortality rate of $\geq 50\%$ and a mean survival period of 3 and 13 days.
- HRCT shows newly developed ground glass opacities or airspace consolidation superimposed on an underlying usual interstitial pneumonia pattern.
- Differential diagnoses, include heart failure, drug toxicity, bilateral pneumonia, and pulmonary embolism; this presents a challenge for clinicians.
- Treatment regimens for AE-IPF include the use of broad-spectrum antibiotics and high-dose corticosteroids with or without immunosuppressive agents, despite the limited evidence of the effectiveness of these therapies.
- New treatment strategies to slow down the progression of IPF may be effective in the prevention of AE-IPF.

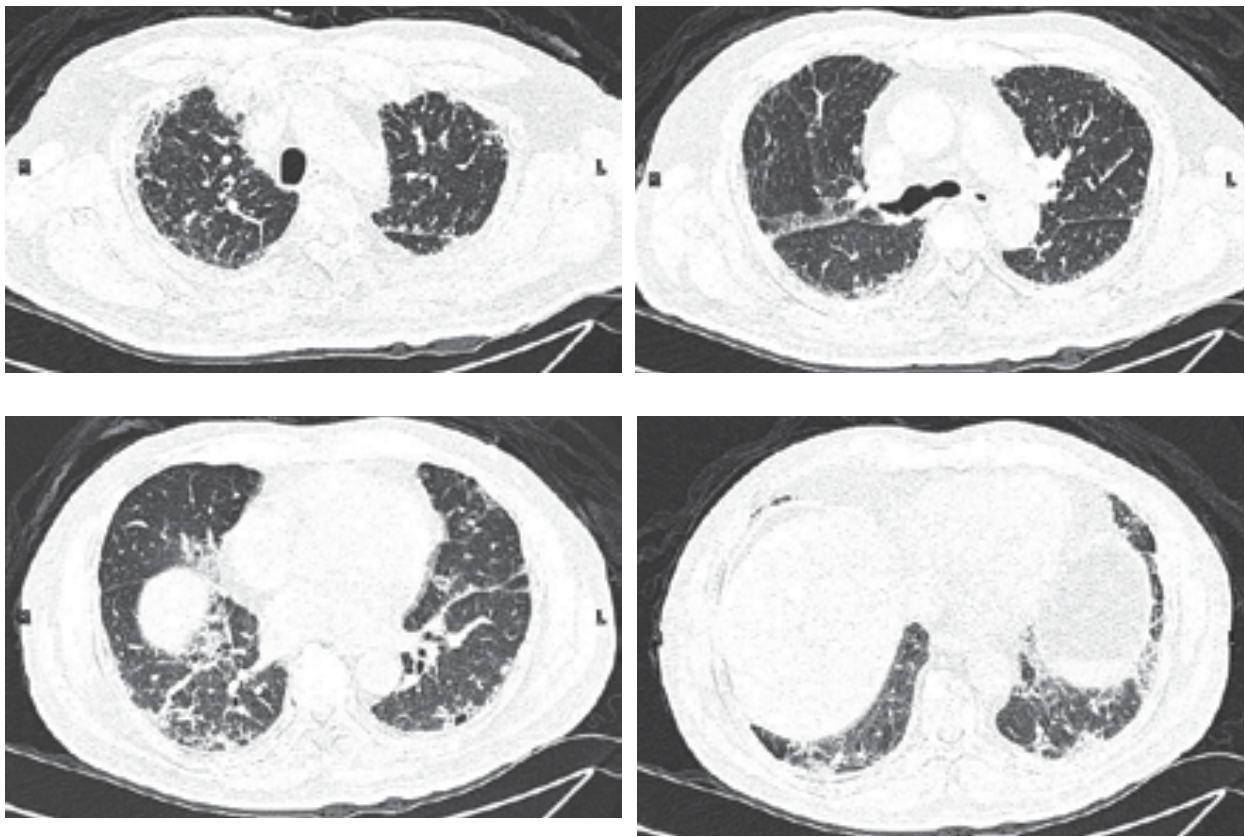
Patient profile

- 73-year-old Chinese, man with a previous smoking history
- Date of admission: May 18, 2015
- Chief complaint: worsening dyspnea since 1 day

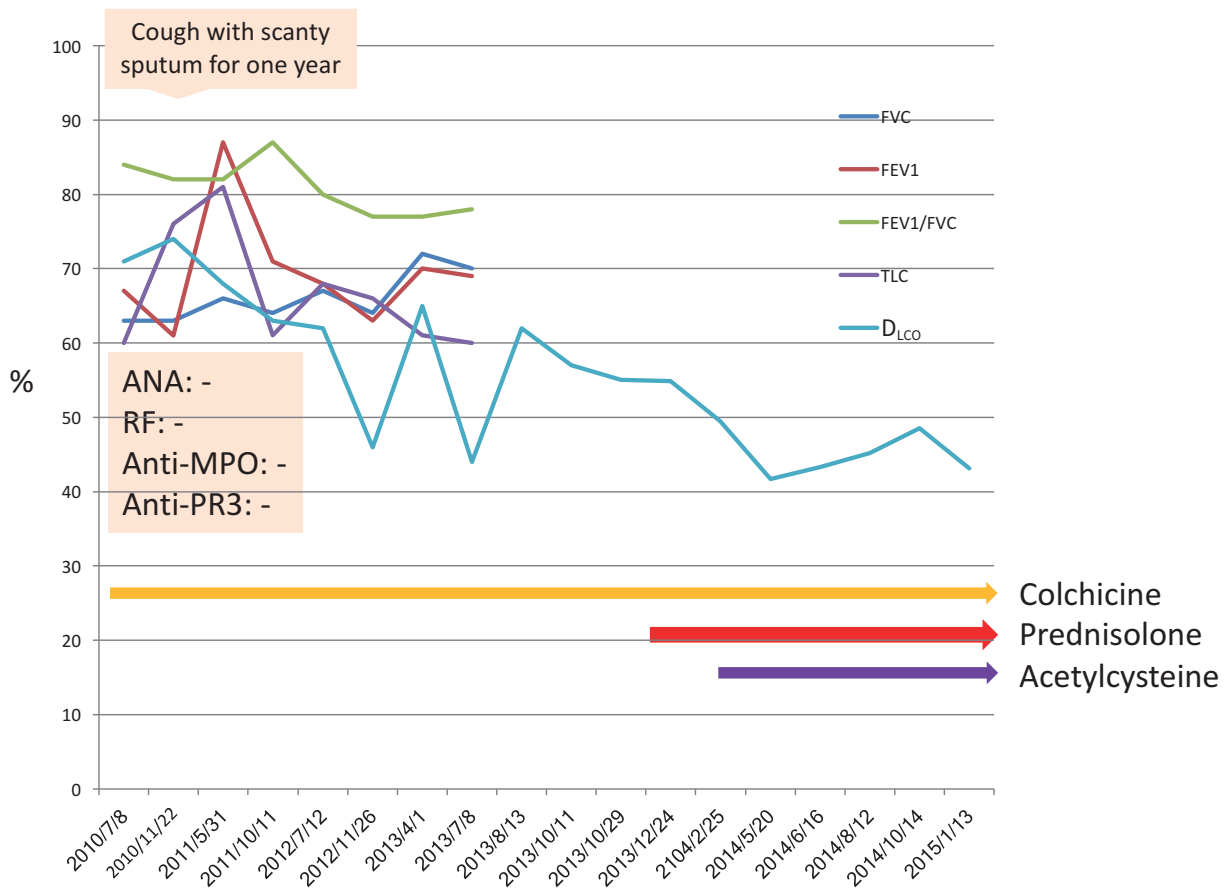
Medical history

- Initial presentation of coughing with scanty sputum for 1 year
- IPF was diagnosed on the basis of serial CXRs obtained from May 2010 up to the time of admission, which showed the progression of interstitial fibrosis over the bilateral peripheral lungs.
- Chest HRCT performed in May 2010 supported the diagnosis of IPF, although no lung biopsies were performed.
- Serial spirometry was performed and D_{LCO} values were recorded, although the patient declined spirometry after 2012.



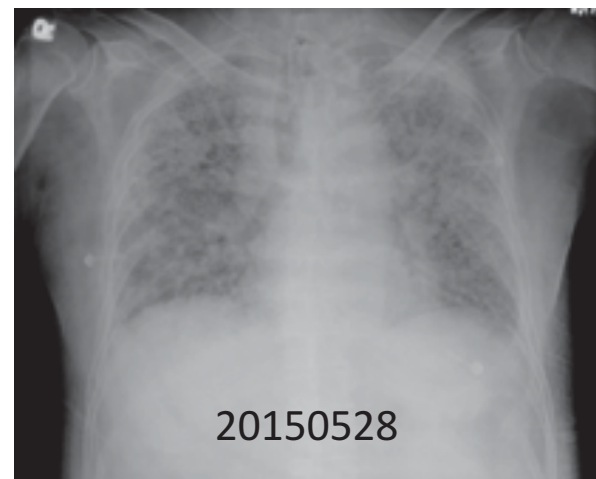
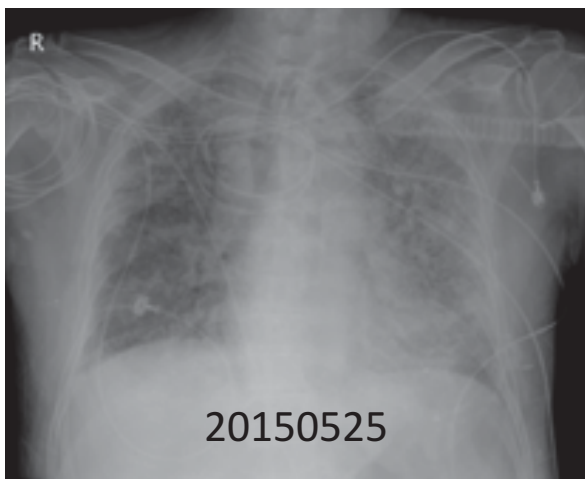
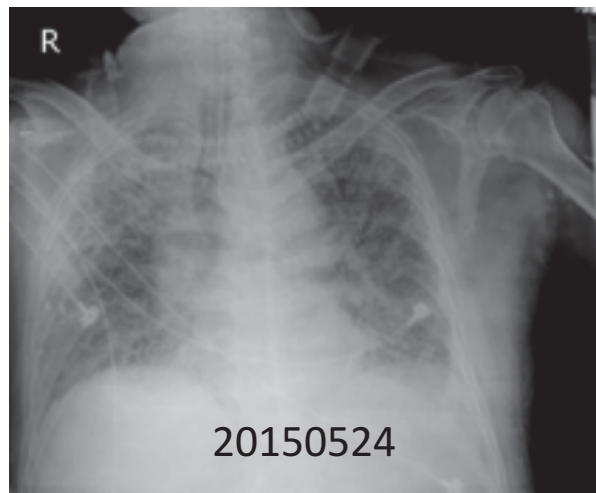
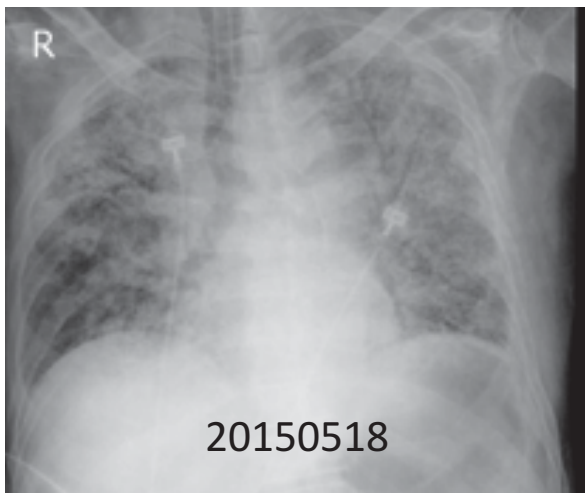


20100522



Hospital course

- Despite mechanical ventilator support and the administration of steroids and broad-spectrum antibiotics, the patient's CXRs showed rapid deterioration of the bilateral pulmonary consolidation superimposed on the extensive interstitial fibrosis.
- All tests for immunological diseases and pathogens revealed negative findings.
- On day 11 of hospitalization, on request by the patient's family, the patient was transferred to another hospital in China with the hope for lung transplantation. He passed away 2 weeks later.



Laboratory findings

Blood test	Result
Hematocrit	41.6%
Hemoglobin g/dL	14.3
White blood cell count, $\times 10^3/\mu\text{L}$	12290
Neutrophils	81.9%
Lymphocytes	11.7%
Eosinophils	0.7%
Monocytes	5.5%
Sodium, mmol/L	4.0
Potassium, mmol/L	132
Glucose, mg/dL	207

Laboratory findings

Date	Sample	Test	Result
5/19	Blood	Mycoplasma P. Ab	-
		H.S.V. 1 & 2	-
		CMV(PCR)	-
5/19	Sputum	P. jirovecii	
		Chlamydia Ag	
5/26	Nasopharyngeal swab	RT-PCR for influenza A virus	
	Nasopharyngeal swab	RT-PCR for influenza B virus	
	Sputum	Virus isolation and identification	
5/26	Blood	ANA	-
		Anti-SM Ab	1.0
		Anti-RNP Ab	0.5
		Anti-RO	0.4
		Anti-La	0.4
		Anti-dsDNA	1.5
		Anti histone	-
		Anti-SLC-70	0.0
		Jo-1	0.0
		Anti-MPO	0.2
		Anti-PR3	0.0
		RF-RIA	<11.5

Respiratory care

Date	ER	5/18	5/19	5/20	5/22	5/23	5/25	5/27	5/28
Mode	Non-REBR mask	PCV	PCV	PS+SIMV	PS+SIMV	PCV	PCV	PCV	PCV
FiO ₂ /PEEP		100/8	80/8	50/8	60/8	75/10	70/10	80/10	85/10
PaO ₂ /FiO ₂		139	228	142	218	74	108	156	103
pH	7.275	7.40	7.34	7.27	7.4	7.46	7.31	7.312	7.383
PaCO ₂	60.1	35	45	63	55	50	75	50.3	49.6
HCO ₃	23.4	21.7	24.3	28.9	34.1	35.6	37.8	25.6	39.9
PaO ₂	59.8	139	183	71	131	56	76	124.9	87.6

Solu Tisone 

References

1. Juarez MM, Chan AL, Norris AG, Morrissey BM, Albertson TE. Acute exacerbation of idiopathic pulmonary fibrosis—a review of current and novel pharmacotherapies. *J Thorac Dis* 2015;7(3):499–519.
2. Kondoh Y, Cottin V, Brown KK. Recent lessons learned in the management of acute exacerbation of idiopathic pulmonary fibrosis. *Eur Respir Rev* 2017;26(145): pii: 170050. doi: 10.1183/16000617.0050-2017
3. Luppi F, Cerri S, Taddei S, Ferrara G, Cottin V. Acute exacerbation of idiopathic pulmonary fibrosis: a clinical review. *Intern Emerg Med* 2015;10(4):401-411.
4. Furuya K, Sakamoto S, Shimizu H, Sekiya M, Kinoshita A, Isshiki T, Sugino K, Matsumoto K, Homma S. Pirfenidone for acute exacerbation of idiopathic pulmonary fibrosis: A retrospective study. *Respir Med* 2017;126:93-99.



End-stage IPF

**Nonpharmacological therapies
and palliative care issues for
patients with end-stage
idiopathic pulmonary fibrosis**

Dr. Pin-Kuei Fu

Department of Critical Care Medicine,
Taichung Veterans General Hospital,
Taichung, Taiwan

Clinical pearls

- IPF is a progressive and ultimately fatal lung disease characterized by dyspnea, cough, and impaired quality of life.
- The optimal nonpharmacological management strategy for IPF should include treatment for comorbidities, symptom relief measures, pulmonary rehabilitation, and palliative care.
- Patients with IPF and clinically significant resting hypoxemia should be treated with long-term oxygen therapy (strong recommendation, very low-quality evidence).
- Mechanical ventilation should not be attempted for the majority of patients with respiratory failure due to IPF; however, it may be a reasonable intervention for a minority of patients (weak recommendation, low-quality evidence).
- International guidelines provide weak recommendations for pulmonary rehabilitation in the majority of patients with IPF, as the long-term effects of pulmonary rehabilitation in IPF have not yet been established. However, there is a growing body of evidence demonstrating short-term benefits, including improvements in exercise capacity, dyspnea and quality of life and patients satisfactions.

Patient profile

Case presentation

- 66-year-old man
- A factory worker residing in central Taiwan
- Intermittent dry cough and progressive dyspnea on exertion during the last 3 years
- Concomitant weight loss of 5 kg

Medical history

- History of peptic ulcer disease treated with proton pump inhibitors
- History of tobacco use, onepack per day for 20 years
- Quit smoking form more than 10 years
- No pets
- Unremarkable-family history

Physical examination

- Heart rate: 106 bpm
- SpO₂: 92% under ambient air
- Bibasilar crackles on auscultation
- Nail clubbing (+)
- No lower extremity edema
- No arthralgia
- No skin rashes

Laboratory findings

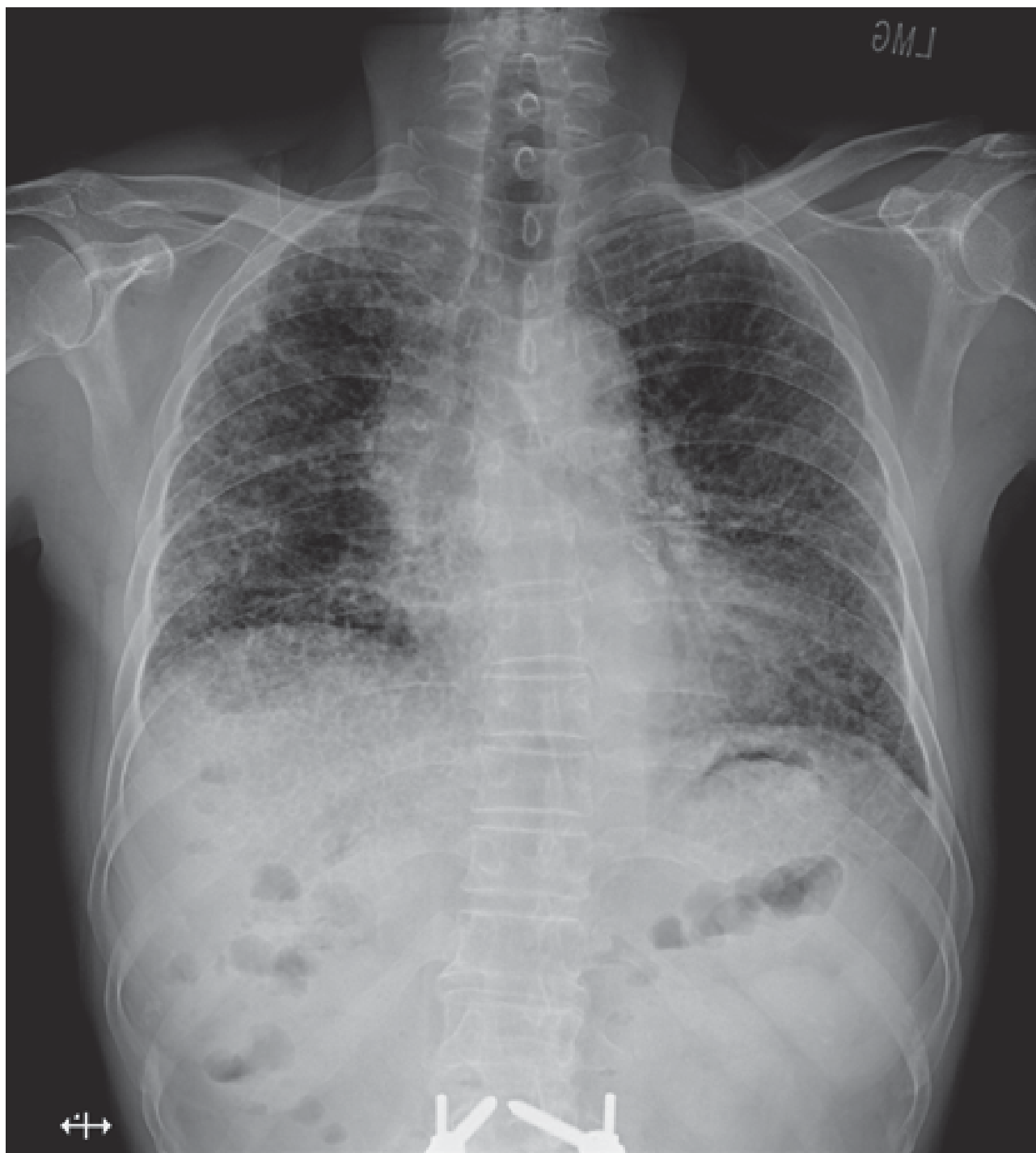- Normal CBC and biochemistry results
- RF, ANA, anti-ENA, and anti-CENP negativity; normal C3 and C4 levels
- Negative bacterial, mycobacterial, and fungal cultures

Pulmonary function test findings

Parameter	Value
FVC	68% predicted
FEV ₁	71% predicted
FEV ₁ /FVC	87%
FEV _{25%-75%}	84%
TLC	69% predicted
D _{Lco}	51% predicted

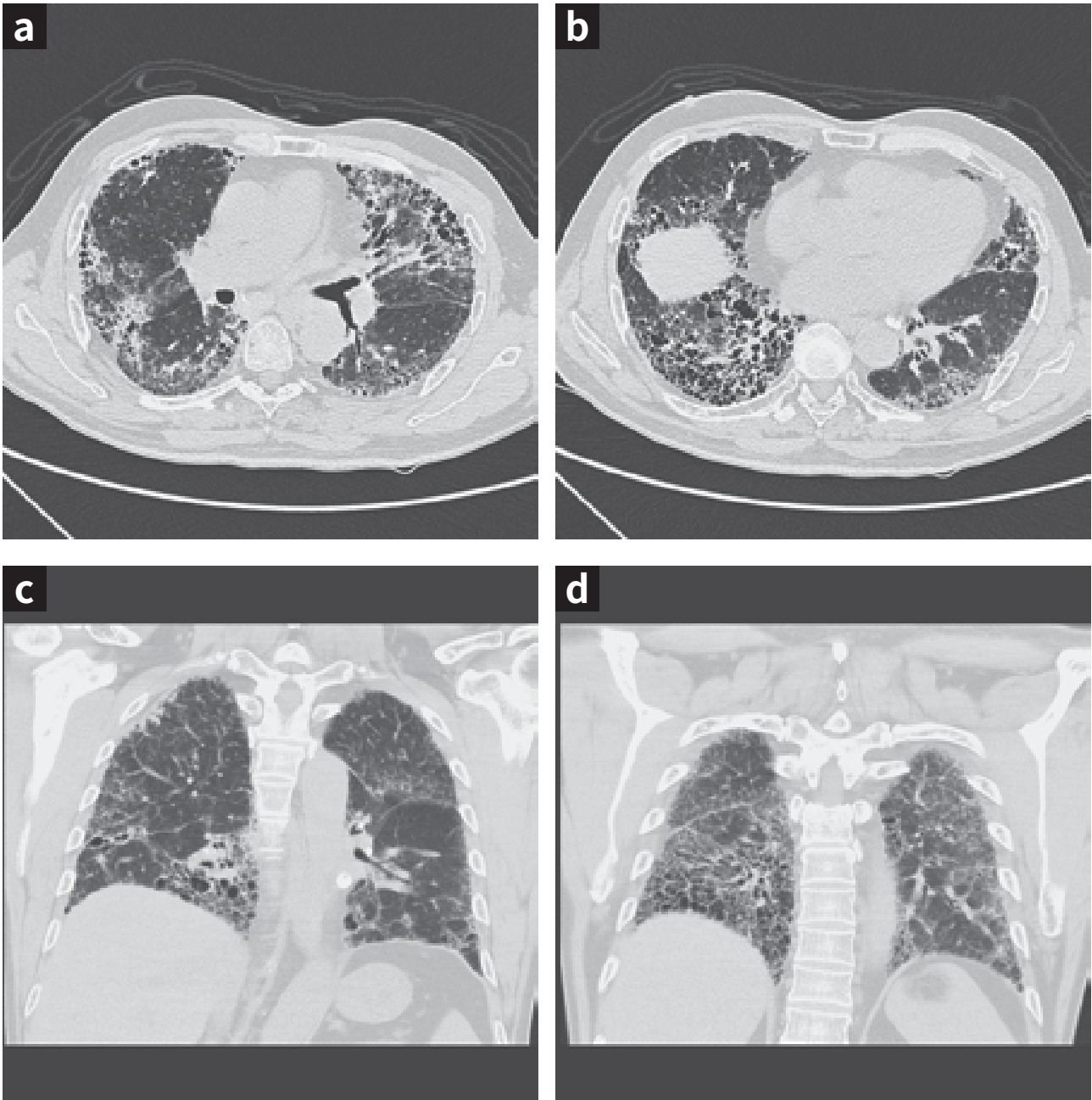
Conclusion: Moderate decrease in TLC and severe decrease in D_{LCO}

Figure1: Chest radiograph findings



Reticular infiltrates distributed equally in both lungs. They are more at the lung periphery, without obvious discrepancy in the upper and lower segments.

Figure 2a-2d: High-resolution computed tomography findings



A UIP pattern can be observed, with bilateral reticular thickening and a honeycomb pattern in the typical apico-postero-basal gradient; Bilateral subpleural bullae can be seen within the honeycomb pattern.


Pulmonary function test findings and care plan- (serial follow-up findings)

Date	FVC (L)	FVC (% predicted)	FEV ₁ (L)	FEV ₁ (% predicted)	D _{LCO} (% predicted)
2015.04	2.24	73	1.87	76	77
<ul style="list-style-type: none"> Beginning of arrangements for Pulmonary rehabilitation 					
2015.08	2.02	68	1.70	71	51
<ul style="list-style-type: none"> Initiation of O₂ therapy at home for symptom relief Pneumococcus Vaccination with PCV-13 Influenza vaccination 					
2015.12	1.98	66	1.64	68	52
2016.03	1.90	62	1.40	58	52
2016.06	1.65	56	1.34	57	51
<ul style="list-style-type: none"> Initiation fo nintedanib 150mg twice a day in July 2016 					
2016.08	1.54	52	1.31	55	41
<ul style="list-style-type: none"> Management of the side effect of diarrhea and impaired liver function 					
2016.11	1.45	50	1.31	56	44
2017.03	Poor effort and poor cooperation to perform lung function test				
<ul style="list-style-type: none"> Family meeting and proposal of an advanced care plan Do not resuscitate request and palliative care consultation during hospitalization Discharge from the hospital with noninvasive positive pressure ventilation support 					
2017.08	Patient passed away at home				

Figure 3: Flowchart showing the nonpharmacological therapies and palliative care measures attempted before death.

Patient management and clinical course

- 2015.05: Started to arrange Pulmonary rehabilitation
- 2015.09: Home O2 therapy,
- 2015.10: Pneumococcus and influenza Vaccination
- 2016.07: Start to treat with Nintedanib 150mg q12h
- 2016.08: Side effect of Nintedanib management
- 2017.03: Family meeting, ACP discussion, NIPPV using
- 2017.05: Passed away at home

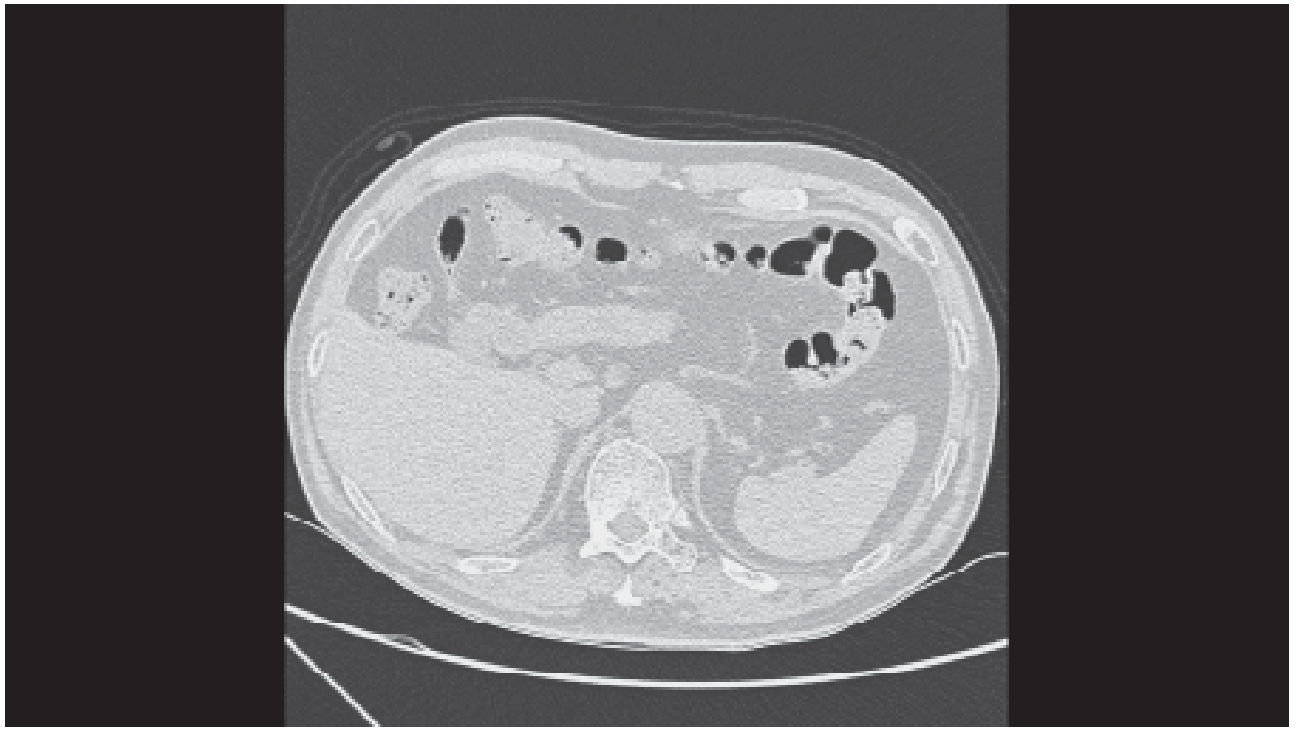


Abbreviations

ACP: advanced care plan, NIPPV: noninvasive positive pressure ventilation

References

1. Raghu G, Richeldi L. Current approaches to the management of idiopathic pulmonary fibrosis. *Respir Med.* 2017; 129:24-30.
2. Raghu G, Rochwerg B, Zhang Y, Garcia CA, Azuma A, Behr J, et al. An Official ATS/ERS/JRS/ALAT Clinical Practice Guideline: Treatment of Idiopathic Pulmonary Fibrosis. An Update of the 2011 Clinical Practice Guideline. *Am J Respir Crit Care Med.* 2015;192(2):e3-19.
3. Raghu G, Collard HR, Egan JJ, Martinez FJ, Behr J, Brown KK, et al. An official ATS/ERS/JRS/ALAT statement: idiopathic pulmonary fibrosis: evidence-based guidelines for diagnosis and management. *Am J Respir Crit Care Med.* 2011;183(6):788-824.



IPF CASE BOOK

VOL.1

特發性肺纖維化案例集

發行單位：台灣胸腔暨重症加護醫學會

地址：10048 台北市中正區常德街 1 號 台大景福館

電話：02-2314-4089

傳真：02-2314-1289

網址：www.tspccm.org.tw

發行人：余忠仁

總編輯：王鶴健

編輯委員：柯信國、高國晉、許超群、傅彬貴、溫岳峰 (依姓氏筆畫排列)

醫學影像編輯：張允中

撰稿人：黃堂修、高國晉、潘奕宏、林基正、張立群、張立禹、王鶴健、徐武輝、陳家弘、
郭炳宏、溫岳峰、劉景隆、許超群、陶啟偉、柯信國、彭萬誠、傅彬貴

出版社：臻呈文化行銷有限公司

地址：10050 台北市中正區忠孝東路二段 14 號二樓

電話：02-2351-2311

傳真：02-2351-2391

網址：www.crossroad.com.tw

出版日期：西元 2017 年 12 月 初版

ISBN:978-986-95806-0-1



台灣胸腔暨重症加護醫學會

Taiwan Society of Pulmonary and Critical Care Medicine



Boehringer
Ingelheim

台灣百靈佳殷格翰股份有限公司 助印

ISBN 978-986-95806-0-1



9 789869 580601